

Diagnostic Imaging Pathways - Dyspnoea (Chronic)

Population Covered By The Guidance

This pathway provides guidance on imaging patients with chronic dyspnoea.

Date reviewed: February 2012

Date of next review: 2017/2018

Published: February 2012

Quick User Guide

Move the mouse cursor over the **PINK** text boxes inside the flow chart to bring up a pop up box with salient points.

Clicking on the **PINK** text box will bring up the full text.

The relative radiation level (RRL) of each imaging investigation is displayed in the pop up box.

| SYMBOL | RRL | EFFECTIVE DOSE RANGE |
|--|---------|----------------------|
|  | None | 0 |
|  | Minimal | < 1 millisieverts |
|  | Low | 1-5 mSv |
|  | Medium | 5-10 mSv |
|  | High | >10 mSv |

Pathway Diagram

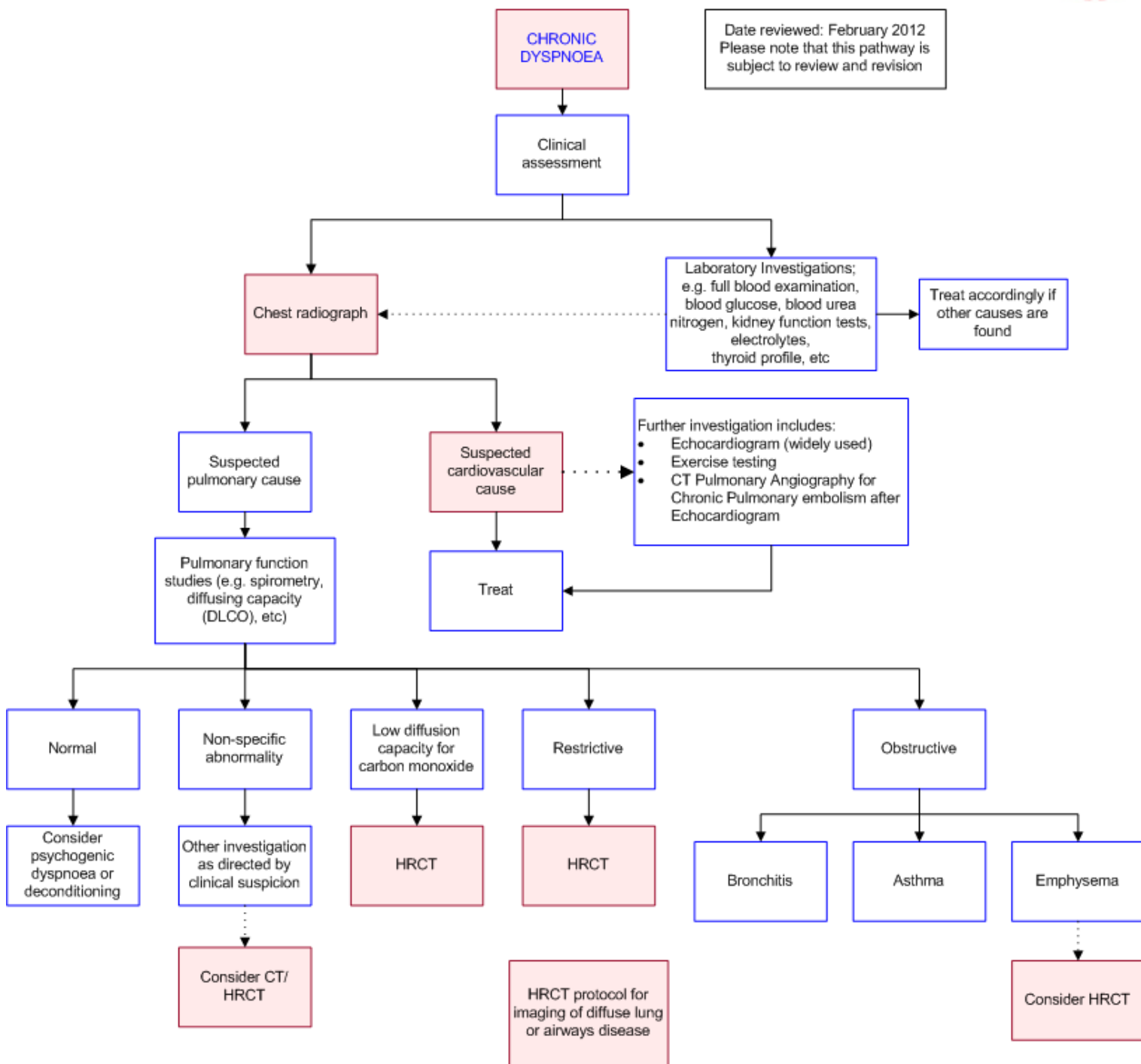


Image Gallery

Note: Images coming soon.

Teaching Points

- Chronic dyspnoea is defined as dyspnoea lasting more than one month
- Plain chest radiography provides useful information in the majority of cases to justify its routine use

- Indications for CT / HRCT include
 - Restrictive lung disease
 - Preoperative assessment of patients who are being referred for lung reduction surgery
 - Patients who have dyspnoea and reduced single-breath diffusing capacity for carbon monoxide without evidence of airflow obstruction
 - Patients with chronic dyspnoea in whom the initial evaluation (clinical assessment, CXR and pulmonary testing) is non diagnostic or non revealing

Chronic Dyspnoea

- Defined as dyspnoea lasting for more than one month and can be caused by a wide range of conditions [1](#)
- Over two thirds of cases are caused by pulmonary or cardiac aetiology with the most common causes being asthma, interstitial lung disease, COPD and myocardial dysfunction [2](#)
- The history and examination will usually provide clues to the underlying diagnosis and direct investigation

Cardiac Dyspnoea

- Cardiac dyspnoea or cardiovascular dyspnoea includes causes of dyspnoea which relate to the cardiac pump and its associated vasculature. It is common to have combined cardiac and other causes of dyspnoea co-existing in a patient especially along with the pulmonary causes. Cardiac dyspnoea is generally evaluated with electrocardiography, laboratory blood tests (N-Brain natriuretic peptide), echocardiography, Holter monitoring, cardio-pulmonary exercise testing and cardiac catheterisation [1](#)

Electrocardiography

- Easily available, non-invasive, inexpensive and quick
- Can show abnormalities in heart rate and rhythm and in addition can detect cardiac ischemia, chamber enlargement and pericardial diseases [1](#)

Holter Monitoring

- A 24 hour or sometimes upto 72 hour recording of heart rhythm in cases suspected for arrhythmias is another inexpensive, relatively readily available and a non-invasive test

Brain Natriuretic Peptide (BNP)

- Blood test, relatively quick and obtainable
- BNP is a hormone present in cardiac musculature especially ventricles. BNP is released when the ventricles are under tension as occurs in heart failure and this can be used as a predictor of the presence as well as to estimate the severity of the failure based on the levels of BNP in the test sample [12](#)

Echocardiography (Echo)

- Relatively easily available, relatively quick. No radiation involved

- Trans-thoracic echocardiography is non-invasive whereas trans-oesophageal echocardiography is invasive
- Echo is the most widely used imaging modality to investigate cardiac failure. Can detect both right and left heart failure, valvular heart diseases and pericardial diseases. Stress echo test can be used to detect cardiac ischemia. Colour flow Doppler echo can be used to detect chronic thromboembolic disease and pulmonary hypertension
- In one study it was noted that 2/3rd of elderly adults with unexplained dyspnoea after history, physical examination, chest radiograph and lung function tests had diastolic dysfunction on echocardiography [13](#)

Cardio-pulmonary exercise testing (CPET)

- Cardio-pulmonary exercise testing is an advanced physiological multi-system testing modality which is relatively non-invasive but less widely available compared to the above tests
- CPET is usually done in cases with high clinical suspicion but equivocal test results or in whom multiple causes may co-exist for dyspnoea and is also very useful in detecting deconditioning and primary hyperventilating syndromes [1,14](#)

Chest Computed Tomography (CT)

- Use of helical multi-detector CT with thin collimation instead of conventional high resolution CT has the advantage of contiguous data acquisition, but at a significantly higher radiation dose. However, studies with MDCT for conditions causing chronic dyspnoea have not been widely published in the literature as yet
- Choice of scanning technique depends on the clinical scenario and the age of the patient. Younger patients (especially females) should have HRCT if clinically acceptable

Interstitial Lung Disease

- HRCT uses narrow 1-2mm collimation (section thickness) every 10-20mm throughout the thorax. While effectively only 10% of the lung is imaged, this a sufficient sample to detect the diffuse parenchymal abnormalities which characterise ILD and minimises the radiation dose delivered to patients [5](#)
- HRCT features of usual interstitial pneumonia (the radiopathological pattern associated with idiopathic pulmonary fibrosis) include irregular reticular lines, traction bronchiectasis, irregular lines and honeycombing in a basilar distribution [5,6](#)
- Overall HRCT has high sensitivity 77-79% and specificity 72-90% with a positive predicted value of 85-88% in diagnosing IPF when compared with histological specimens obtained at lung biopsy as the gold standard [7,8](#)
- The sensitivity, specificity and PPV of a confident radiological diagnosis of IPF (ie. when uncertain cases are excluded) rises to 87%, 95% and 96% respectively [7](#)
- The sensitivity and specificity of ILD other than IPF is significantly lower at 59% and 40% respectively [8](#)
- Based on the studies above, surgical lung biopsy remains the gold standard for accurate diagnosis of ILD when the diagnosis is uncertain, and when the clinical diagnosis is and ILD other than IPF [5,7,8](#)

Emphysema

- Superior to plain radiography in showing the presence, distribution and extent of emphysema [4,9](#)
- Although conventional or spiral CT can detect most cases of emphysema, HRCT is more reliable [4](#)
- Emphysema is characterised by areas of abnormally low attenuation on HRCT [4,9](#)
- Mild early emphysematous change may be missed on HRCT (low sensitivity), however it is still superior to pulmonary function testing in detecting the presence of emphysema and correlating with the severity of disease [9](#)
- The grading of emphysema based on HRCT findings correlated well with pathological severity in several studies and is in the order of 0.7-0.9
- The role of CT in the clinical assessment of emphysema is limited by its expense. The main indications for the use of CT in assessing emphysema are
 - Preoperative assessment of patients who are being referred for lung reduction surgery [9](#)
 - Patients who have dyspnoea and reduced single-breath diffusing capacity for carbon monoxide without evidence of airflow obstruction [9,10,11](#)

Non-specific Abnormalities

- CT scanning should be considered in patients with chronic dyspnoea when the initial evaluation (clinical assessment, chest radiography and pulmonary testing) is non diagnostic or non revealing [3](#)
- This should be weighed against the radiation exposure risk, particularly in young patients

Chest Radiograph

- Can reveal enough useful information regarding the diagnosis to justify its routine use in the initial investigation of chronic dyspnoea [3](#)
- Used to exclude or demonstrate obvious chest wall abnormality (e.g. severe kyphoscoliosis, pectus excavatum) and/or help direct further investigations.
- One study found a positive predictive value of 75% and negative predictive value of 91% in the diagnosis of all causes of chronic dyspnoea [2](#)
- Plain radiography had a sensitivity of 97% in diagnosis of symptomatic patients with moderate to severe emphysema based the radiological signs of hyperinflation and vascular alterations. However, its usefulness in diagnosis of mild emphysema is limited with low sensitivity and specificity [4](#)
- Although chest radiography may be normal in patients with chronic dyspnoea due to interstitial lung disease, one study found interstitial changes on plain film in all 12 of their patients who had ILD [2](#)

References

References are graded from Level I to V according to the Oxford Centre for Evidence-Based Medicine, Levels of Evidence. [Download the document](#)

- [1.](#) Karnani NG, Reisfield GM, Wilson GR. **Evaluation of chronic dyspnea.** Am Fam Physician. 2005;71(8):1529-37. (Review article)
- [2.](#) Pratter MR, Curley FJ, Dubois J, Irwin RS. **Cause and evaluation of chronic dyspnea in a pulmonary disease clinic.** Arch Intern Med. 1989;149(10):2277-82. (Level IV evidence)
- [3.](#) Westcott J, Davis SD, Fleishon H, Geffer WB, Henschke CI, McCloud TC, et al. **Dyspnea. American College of Radiology. ACR Appropriateness Criteria.** Radiology. 2000;215 Suppl:641-3. (Review article)
- [4.](#) Muller NL, Coxson H. **Chronic obstructive pulmonary disease. 4: imaging the lungs in**



- patients with chronic obstructive pulmonary disease.** Thorax. 2002;57(11):982-5. (Review article)
5. Gotway MB, Freemer MM, King TE, Jr. **Challenges in pulmonary fibrosis. 1: Use of high resolution CT scanning of the lung for the evaluation of patients with idiopathic interstitial pneumonias.** Thorax. 2007;62(6):546-53. (Review article)
 6. Hunninghake GW, Lynch DA, Galvin JR, Gross BH, Muller N, Schwartz DA, et al. **Radiologic findings are strongly associated with a pathologic diagnosis of usual interstitial pneumonia.** Chest. 2003;124(4):1215-23. (Level II evidence). [View the reference](#)
 7. Hunninghake GW, Zimmerman MB, Schwartz DA, King TE, Jr., Lynch J, Hegele R, et al. **Utility of a lung biopsy for the diagnosis of idiopathic pulmonary fibrosis.** Am J Respir Crit Care Med. 2001;164(2):193-6. (Level II evidence). [View the reference](#)
 8. Raghu GG, Margeto YYN, Lockhart DD, Schmidt RRA, Wood DDE, Godwin JJD. **The accuracy of the clinical diagnosis of new-onset idiopathic pulmonary fibrosis and other interstitial lung disease: a prospective study.** Chest. 1999;116(5):1168-74. (Level II evidence). [View the reference](#)
 9. Thurlbeck WM, Muller NL. **Emphysema: definition, imaging, and quantification.** AJR Am J Roentgenol. 1994;163(5):1017-25. (Review article)
 10. Orens JB, Kazerooni EA, Martinez FJ, Curtis JL, Gross BH, Flint A, et al. **The sensitivity of high-resolution CT in detecting idiopathic pulmonary fibrosis proved by open lung biopsy. A prospective study.** Chest. 1995;108(1):109-15. (Level II evidence). [View the reference](#)
 11. DePaso WJ, Winterbauer RH, Lusk JA, Dreis DF, Springmeyer SC. **Chronic dyspnea unexplained by history, physical examination, chest roentgenogram, and spirometry. Analysis of a seven-year experience.** Chest. 1991;100(5):1293-9. (Level IV evidence)
 12. Wiecek SJ, Wu AH, Christenson R, Krishnaswamy P, Gottlieb S, Rosano T, et al. **A rapid Btype natriuretic peptide assay accurately diagnoses left ventricular dysfunction and heart failure: a multicenter evaluation.** Am Heart J. 2002;144:834-9. (Level III evidence)
 13. Penicka M, Bartunek J, Trakalova H, et al. **Heart failure with preserved ejection fraction in outpatients with unexplained dyspnea: a pressure-volume loop analysis.** J Am Coll Cardiol. 2010;55:1701. (Level IV evidence)
 14. **ATS/ACCP Statement on cardiopulmonary exercise testing.** Am J Respir Crit Care Med. 2003;167:211-77. (Practice guidelines)

Information for Consumers

| Information from this website | Information from the Royal Australian and New Zealand College of Radiologists' website |
|---|--|
| <p>Consent to Procedure or Treatment</p> <p>Radiation Risks of X-rays and Scans</p> <p>Computed Tomography (CT)</p> <p>Chest Radiograph (X-ray)</p> | <p>Computed Tomography (CT)</p> <p>Iodine-Containing Contrast Medium</p> <p>Plain Radiography/X-rays</p> <p>Radiation Risk of Medical Imaging During Pregnancy</p> |

[Radiation Risk of Medical Imaging for
Adults and Children](#)

Copyright

© Copyright 2015, Department of Health Western Australia. All Rights Reserved. This web site and its content has been prepared by The Department of Health, Western Australia. The information contained on this web site is protected by copyright.

Legal Notice

Please remember that this leaflet is intended as general information only. It is not definitive and The Department of Health, Western Australia can not accept any legal liability arising from its use. The information is kept as up to date and accurate as possible, but please be warned that it is always subject to change

File Formats

Some documents for download on this website are in a Portable Document Format (PDF). To read these files you might need to download Adobe Acrobat Reader.



[Legal Matters](#)