

# Diagnostic Imaging Pathways - Bronchiectasis

## Population Covered By The Guidance

This pathway provides guidance on imaging patients with suspected bronchiectasis.

**Date reviewed: April 2018**

**Date of next review: April 2021**






**Published: June 2018**

## Quick User Guide

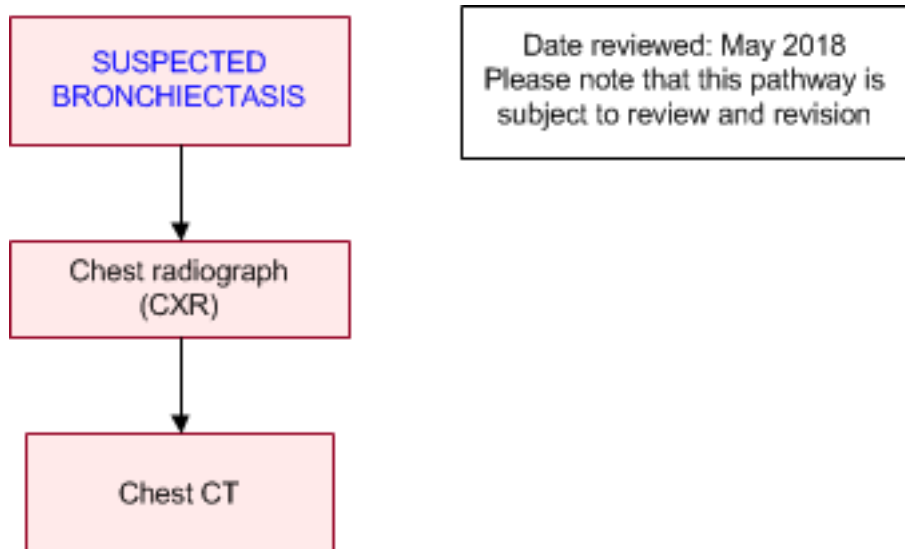
Move the mouse cursor over the PINK text boxes inside the flow chart to bring up a pop up box with salient points.

Clicking on the PINK text box will bring up the full text.

The relative radiation level of each imaging investigation is displayed in the pop up box.

SYMBOL	RRL	EFFECTIVE DOSE RANGE
	None	0
	Minimal	< 1 millisieverts
	Low	1-5 mSv
	Medium	5-10 mSv
	High	>10 mSv

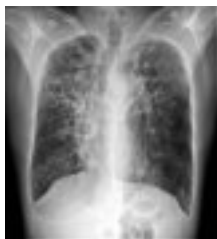## Pathway Diagram



## Image Gallery

*Note: These images open in a new page*

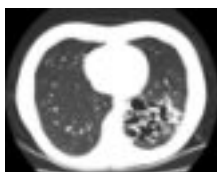1a



### Cystic Bronchiectasis

Image 1 (Plain Radiograph): Severe cystically dilated bronchi most marked in the upper lung zones bilaterally due to cystic fibrosis.

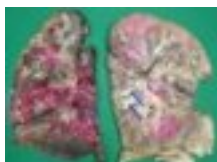2



### Cystic Bronchiectasis

Image 2 (Computed Tomography): Multicystic space within the base of the left lower lobe which is continuous with the small airways and is representative of cystic bronchiectasis.

3a



### Cystic Bronchiectasis

Image 3a: Pneumonectomy showing grossly dilated bronchi with mucous plugging (blue arrows) and distal consolidation.

3b



Image 3b (H&E, x2.5): Section of a dilated bronchi with florid acute on chronic inflammation of the bronchial wall and surrounding interstitial fibrosis.

## Teaching Points

- Bronchiectasis is a clinical syndrome involving irreversible damage and dilatation of the bronchi
  - The diagnosis of bronchiectasis requires the presence of clinical symptoms as well as characteristic radiographic features on chest CT
- A chest radiograph is useful to exclude other causes of the patient's symptoms. In severe disease, it can demonstrate changes of bronchiectasis
- Chest CT is the investigation of choice to define the type and extent of bronchiectasis

## Bronchiectasis

- Bronchiectasis is a clinical syndrome involving irreversible damage and dilatation of the bronchi [1](#)
- The diagnosis of bronchiectasis requires the presence of clinical symptoms as well as characteristic radiographic features on Chest CT [1](#)
- Bronchiectasis may be described as a final common pathway for several diseases associated with excessive bronchial inflammation, bacterial colonisation and infection. [2](#) Cystic fibrosis is the most recognised cause of bronchiectasis, [3](#) however, the prevalence of non-CF bronchiectasis is increasing. [4](#) Causes of non-CF bronchiectasis include primary antibody deficiency syndromes, certain infections, autoimmune conditions and other mucociliary clearance defects. [2, 3](#)

Bronchiectasis is becoming increasingly associated with COPD, and is associated with poor outcomes when present [5](#)

## Plain Chest Radiograph (CXR)

- Relatively insensitive for bronchiectasis, but usually the initial investigation to exclude other causes for the patient's symptoms [6, 7](#)
- Compared to CT, CXR has a reported sensitivity of 88% and specificity of 74% [8, 9](#)
- May be normal in mild disease and underestimates the severity and extent of the disease [6, 7, 10, 11](#)
- Bronchiectasis patients commonly have abnormal CXR appearances but changes are often non-specific. [2](#) Findings suggestive of bronchiectasis include “tram track” appearance of dilated bronchi radiating from the hila, bronchial wall thickening and nodular or tubular opacities representing mucous impaction, [12, 13](#) however, these signs may also represent COPD, asthma or lower respiratory tract infection. [10](#) There may also be evidence of chronic lower airway infection such as calcifications or infiltrates [4](#)
- A baseline CXR is recommended in all bronchiectasis patients with repeat CXR based on clinical need, but CT is recommended to establish the diagnosis [10](#)
- There is poor correlation with infective exacerbations of bronchiectasis and radiographic changes [14](#) and exacerbations are usually defined by clinical signs and symptoms [10](#)

## Chest Computed Tomography (CT)

- CT Chest is the investigation of choice for diagnosing bronchiectasis [1, 10](#)
- CT can identify classify bronchiectasis into different morphologies including cylindrical, cystic and varicoid [3, 12](#)
- Typical features of bronchiectasis on CT include: [3, 10, 15-18](#)
  - Lack of tapering of the bronchial lumina
  - Dilated bronchi with internal diameter greater than that of the adjacent pulmonary artery
  - Visualized bronchi within 1 cm of the pleura
  - Mucus-filled dilated bronchi
- Radiographic findings can also point towards the underlying cause [18-20](#) although no aetiology is identified in a large proportion [21](#)
- Conventional HRCT with 1mm thick slices at 10mm intervals was considered the gold standard for diagnosis of bronchiectasis, [10](#) but it has been mostly replaced by multislice CT (or multidetector CT, MDCT) which can be reconstructed into thin slices to assess parenchymal and bronchial detail, and continuous thick slices to assess for small nodules. Multislice CT has a faster acquisition time and higher resolution when reconstructed in different planes. MDCT has been shown to be more accurate for diagnosing bronchiectasis compared to conventional HRCT [22, 23](#) and is preferred [1](#)

## References

**Date of literature search: April 2018**

References are graded from Level I to V according to the Oxford Centre for Evidence-Based Medicine, Levels of Evidence. [Download the document](#)



1. Thoracic Society of Australia and New Zealand. **Chronic suppurative lung disease and bronchiectasis in children and adults in Australia and New Zealand. Clinical practice guideline.** 2014. (Guideline). [View the reference](#)
2. Altenburg J, Wortel K, van der Werf TS, Boersma WG. **Non-cystic fibrosis bronchiectasis: clinical presentation, diagnosis and treatment, illustrated by data from a Dutch Teaching Hospital.** Neth J Med. 2015;73(4):147-54. (Review article). [View the reference](#)
3. Milliron B, Henry TS, Veeraraghavan S, Little BP. **Bronchiectasis: Mechanisms and imaging clues of associated common and uncommon diseases.** Radiographics. 2015;35(4):1011-30. (Review article). [View the reference](#)
4. Maselli DJ, Amalakuhan B, Keyt H, Diaz AA. **Suspecting non-cystic fibrosis bronchiectasis: What the busy primary care clinician needs to know.** Int J Clin Pract. 2017;71(2):e12924. (Review article). [View the reference](#)
5. Martinez-Garcia MA, Soler-Cataluna JJ, Donat Sanz Y, Catalan Serra P, Agramunt Lerma M, Ballestin Vicente J, et al. **Factors associated with bronchiectasis in patients with COPD.** Chest. 2011;140(5):1130-7. (Level III evidence). [View the reference](#)
6. Tasker AD, Flower CD. **Imaging the airways. Hemoptysis, bronchiectasis, and small airways disease.** Clin Chest Med. 1999;20(4):761-73, viii. (Review article). [View the reference](#)
7. Kumar NA, Nguyen B, Maki D. **Bronchiectasis: current clinical and imaging concepts.** Semin Roentgenol. 2001;36(1):41-50. (Review article). [View the reference](#)
8. Munro NC, Han LY, Currie DC, Strickland B, Cole PJ. **Radiological evidence of progression of bronchiectasis.** Respir Med. 1992;86(5):397-401. (Level III evidence). [View the reference](#)
9. van der Bruggen-Bogaarts BA, van der Bruggen HM, van Waes PF, Lammers JW. **Screening for bronchiectasis. A comparative study between chest radiography and high-resolution CT.** Chest. 1996;109(3):608-11. (Level II-III evidence). [View the reference](#)
10. Pasteur MC, Bilton D, Hill AT. **British Thoracic Society guideline for non-CF bronchiectasis.** Thorax. 2010;65 Suppl 1:i1-58. (Guideline). [View the reference](#)
11. Ellis S, Aziz Z. **Radiology as an aid to diagnosis in lung disease.** Postgrad Med J. 2016;92(1092):620-3. (Review article). [View the reference](#)
12. Little BP, Duong PT. **Imaging of diseases of the large airways.** Radiol Clin North Am. 2016;54(6):1183-203. (Review article). [View the reference](#)
13. Cantin L, Bankier AA, Eisenberg RL. **Bronchiectasis.** Am J Roentgenol. 2009;193(3):W158-W71. (Review article). [View the reference](#)
14. Greene KE, Takasugi JE, Godwin JD, Richardson ML, Burke W, Aitken ML. **Radiographic changes in acute exacerbations of cystic fibrosis in adults: a pilot study.** AJR Am J Roentgenol. 1994;163(3):557-62. (Level III evidence). [View the reference](#)
15. Kang EY, Miller RR, Muller NL. **Bronchiectasis: comparison of preoperative thin-section CT and pathologic findings in resected specimens.** Radiology. 1995;195(3):649-54. (Level IV evidence). [View the reference](#)
16. Lynch DA, Newell JD, Tschomper BA, Cink TM, Newman LS, Bethel R. **Uncomplicated asthma in adults: comparison of CT appearance of the lungs in asthmatic and healthy subjects.** Radiology. 1993;188(3):829-33. (Level III evidence). [View the reference](#)
17. Bonavita J, Naidich DP. **Imaging of bronchiectasis.** Clin Chest Med. 2012;33(2):233-48. (Review article). [View the reference](#)
18. Dodd JD, Lavelle LP, Fabre A, Brady D. **Imaging in cystic fibrosis and non-cystic fibrosis bronchiectasis.** Semin Respir Crit Care Med. 2015;36(2):194-206. (Review article). [View the reference](#)
19. Barker AF. **Bronchiectasis.** N Engl J Med. 2002;346(18):1383-93. (Review article). [View the reference](#)
20. Cartier Y, Kavanagh PV, Johkoh T, Mason AC, Muller NL. **Bronchiectasis: accuracy of high-resolution CT in the differentiation of specific diseases.** AJR Am J Roentgenol. 1999;173(1):47-52. (Level II-III evidence). [View the reference](#)



21. Reiff DB, Wells AU, Carr DH, Cole PJ, Hansell DM. **CT findings in bronchiectasis: limited value in distinguishing between idiopathic and specific types.** AJR Am J Roentgenol. 1995;165(2):261-7. (Level II-III evidence). [View the reference](#)
22. Dodd JD, Souza CA, Muller NL. **Conventional high-resolution CT versus helical high-resolution MDCT in the detection of bronchiectasis.** AJR Am J Roentgenol. 2006;187(2):414-20. (Level II evidence). [View the reference](#)
23. Hill LE, Ritchie G, Wightman AJ, Hill AT, Murchison JT. **Comparison between conventional interrupted high-resolution CT and volume multidetector CT acquisition in the assessment of bronchiectasis.** The British Journal of Radiology. 2010;83(985):67-70. (Level II evidence). [View the reference](#)

## Information for Consumers

Information from this website	Information from the Royal Australian and New Zealand College of Radiologists' website
<p><a href="#">Consent to Procedure or Treatment</a></p> <p><a href="#">Radiation Risks of X-rays and Scans</a></p> <p><a href="#">Computed Tomography (CT)</a></p> <p><a href="#">Chest Radiograph (X-ray)</a></p>	<p><a href="#">Computed Tomography (CT)</a></p> <p><a href="#">Iodine-Containing Contrast Medium</a></p> <p><a href="#">Plain Radiography/X-rays</a></p> <p><a href="#">Radiation Risk of Medical Imaging During Pregnancy</a></p> <p><a href="#">Radiation Risk of Medical Imaging for Adults and Children</a></p>

## Copyright

© Copyright 2018, Department of Health Western Australia. All Rights Reserved. This web site and its content has been prepared by The Department of Health, Western Australia. The information contained on this web site is protected by copyright.

## Legal Notice

Please remember that this leaflet is intended as general information only. It is not definitive and The Department of Health, Western Australia can not accept any legal liability arising from its use. The information is kept as up to date and accurate as possible, but please be warned that it is always subject to change



## File Formats

Some documents for download on this website are in a Portable Document Format (PDF). To read these files you might need to download Adobe Acrobat Reader.



[Legal Matters](#)