

# Diagnostic Imaging Pathways - Paediatric, Stridor (Persistent)

## Population Covered By The Guidance

This pathway provides guidance on imaging young children with persistent unexplained stridor.

**Date reviewed: July 2014**

**Date of next review: 2017/2018**






**Published: July 2014**

## Quick User Guide

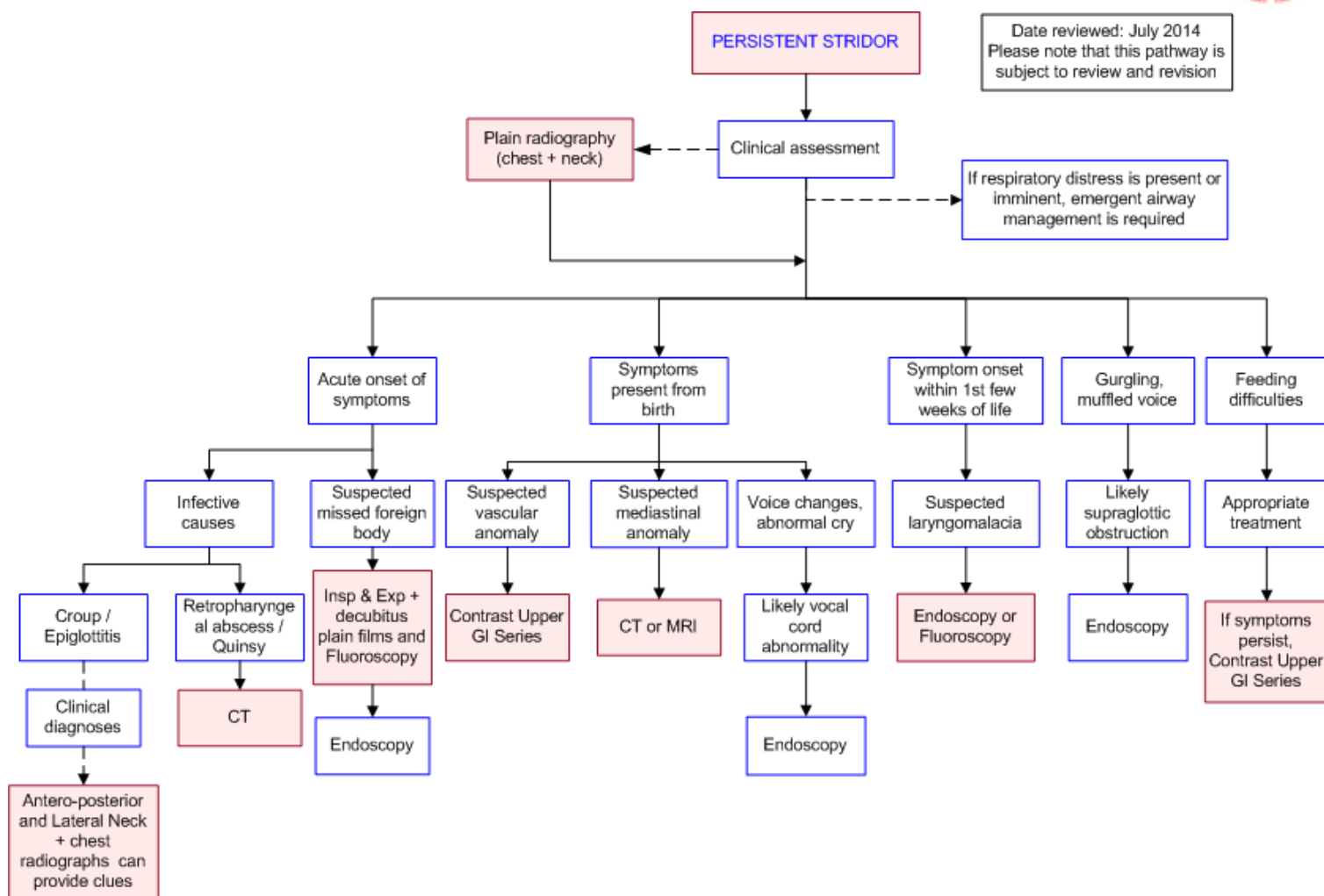
Move the mouse cursor over the PINK text boxes inside the flow chart to bring up a pop up box with salient points.

Clicking on the PINK text box will bring up the full text.

The relative radiation level of each imaging investigation is displayed in the pop up box.

SYMBOL	RRL	EFFECTIVE DOSE RANGE
	None	0
	Minimal	< 1 millisieverts
	Low	1-5 mSv
	Medium	5-10 mSv
	High	>10 mSv

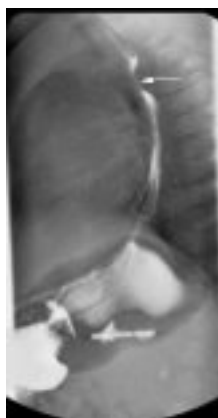## Pathway Diagram



## Image Gallery

*Note: These images open in a new page*

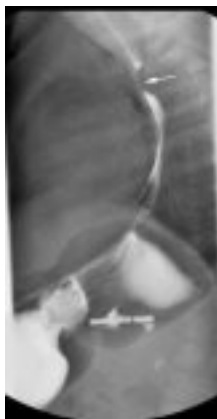1a



### Vascular Anomaly

Image 1a and 1b (Barium Swallow): There is a nasogastric tube in situ. The trachea appears normal. A constant focal narrowing of the posterior oesophagus is seen approximately at the level of the aortic arch with smooth margins (arrow), indicating extrinsic compression of the posterior surface of the oesophagus. This is most suggestive of a vascular anatomic anomaly such as an aberrant retro-oesophageal right subclavian artery causing stridor.

1b



## Teaching Points

- Chronic or persistent stridor lasts for more than 3 weeks or recurs on more than 3 occasions
- Initial investigation of persistent stridor is an antero-posterior and lateral views of the chest and neck
- Further investigations are dictated by the most likely diagnosis, based on the age of the child, the onset of symptoms and findings on clinical history and examination

## Contrast Upper Gastrointestinal Studies

- Primary indication is to detect the presence of vascular rings and slings causing tracheo-oesophageal compression [9](#)
- Gastroesophageal reflux disease appears to be related to upper respiratory symptoms (e.g. stridor) in the paediatric population, although the strength of the relationship is unclear. Treatment of reflux disease may therefore result in an improvement in respiratory symptoms [10,11](#)
- Various patterns of compression have been documented and may suggest the cause for stridor [2, 12](#)

## Cross Sectional Imaging (CT and MRI)

- Cross sectional imaging generally in the form of CT is used for assessing perilaryngeal or mediastinal compressive masses affecting the airway and has largely replaced conventional angiography for investigation of suspected vascular rings [1,12,13](#)
- CT is preferred over MRI because of the long scanning times associated with the latter, requiring young children to be sedated or undergo a general anaesthetic
- Multidetector CT is superior to MRI for assessment of compressive lesions and depicting vascular anatomy. The use of low-dose multidetector CT needs to be studied further, but a case series comparing CT to surgery or endoscopy had an accuracy of 100% [14,15](#)

## Fluoroscopy

- Provides a dynamic assessment of the paediatric airway and allows visualisation of partial obstruction, dynamic causes of airway obstruction. Airway fluoroscopy can evaluate

- hemidiaphragm movements and check for localised air trapping [16](#)
- Usually able to demonstrate features of laryngomalacia, including collapse of the laryngeal and supralaryngeal structures during inspiration [16,17](#)
- Significant role in detecting foreign bodies compared to plain films, with a sensitivity of 73%-80% for subglottic, tracheal, bronchial causes of upper airway obstruction. It is less sensitive for diagnosing foreign bodies at supraglottic and glottic sites [16](#)

## Persistent Stridor

- Stridor refers to a harsh respiratory noise caused by turbulent air passing through a narrowed airway
- Acute stridor develops over minutes and usually resolves in days but may last up to 2 weeks. Chronic or persistent stridor lasts for more than 3 weeks, or recurs on 3 or more occasions [1,2](#)
- The timing of stridor in relation to the respiratory cycle can indicate the location of the narrowing [3,4](#)
  - Inspiratory stridor usually results from obstruction above the level of the glottis
  - Biphasic stridor suggests obstruction in the area between the glottis and subglottis, or fixed/critical obstruction at any level
  - Expiratory stridor is characteristic of intra-thoracic obstructions
- Causes of stridor include [2](#)
  - Foreign body
  - Laryngomalacia
  - Tracheomalacia
  - Laryngotracheobronchitis
  - Vascular rings and slings
  - Subglottic stenosis
  - Laryngeal or tracheal stenosis
  - Congenital laryngeal web
  - Laryngeal cleft
  - Vocal cord palsy
  - Subglottic haemangioma
  - Retropharyngeal abscess/quinsy
  - Tracheo-oesophageal fistula, cystic hygroma
- The gold standard for diagnosing the cause of stridor is direct laryngoscopy and bronchoscopy [1](#)

## Plain Radiography

- The initial investigation for persistent stridor usually involves anteroposterior and lateral views of the neck [4](#)
- Inspiratory and expiratory chest films and decubitus chest films if unable to cooperate with inspiration/expiration are usually done in a PA projection
- High kilovoltage films are required to adequately distinguish between soft tissue and air [3,5](#)
- The sensitivity of plain radiography varies greatly depending on the cause of persistent stridor. Compared to endoscopy, plain radiography has a low sensitivity for functional lesions such as laryngomalacia and tracheomalacia, but this improves for fixed lesions
- A retrospective series found that radiographic findings only correlated with proven endoscopic abnormalities in 18.5% of cases [6](#)
- Inspiratory and expiratory chest films may demonstrate ventilatory differences seen with foreign body aspiration. Sensitivity and specificity for diagnosis of an airway foreign body is 68-73% and

45-67% respectively [4,7,8](#)

## References

References are graded from Level I to V according to the Oxford Centre for Evidence-Based Medicine, Levels of Evidence. [Download the document](#)

1. Landau LI. **Investigation and treatment of chronic stridor in infancy.** Monaldi Arch Chest Dis. 1999;54:18-21. (Review article)
2. Goodman TR, McHugh K. **The role of radiology in the evaluation of stridor.** Arch Dis Child 1999;81:456-9. (Review article).
3. Jasin ME, Osguthorpe JD. **The radiographic evaluation of infants with stridor.** Otolaryngol Head Neck Surg. 1982;90:736-9. (Review article)
4. O'Halloren MT, Everts EC. **Evaluating the patient with stridor.** Ann Allergy. 1991;67:301-5. (Review article)
5. Zalzal GH. **Stridor and airway compromise.** Pediatr Clin North Am. 1989;36:1389-1402. (Review article)
6. Friedman EM, Vastola AP, McGill TJ, Healy GB. **Chronic pediatric stridor: etiology and outcome.** Laryngoscope. 1990;100:277-80. (Level III evidence)
7. Silva AB, Muntz HR, Clary R. **Utility of conventional radiography in the diagnosis and management of pediatric airway foreign bodies.** Ann Otol Rhinol Laryngol. 1998;107:834-8. (Level IV evidence)
8. Svedstrom E, Puhakka H, Kero P. **How accurate is chest radiography in the diagnosis of tracheobronchial foreign bodies in children?** Pediatr Radiol. 1989;19:520-2. (Level III evidence)
9. Tostevin PM, de Bruyn R, Hosni A, Evans JNG. **The value of radiological investigations in the pre-endoscopic assessment of children with stridor.** J Laryngol Otol. 1995;109:844-8. (Level III evidence). [View the reference](#)
10. Rosbe KW, Kenna MA, Auerbach AD. **Extraesophageal reflux in pediatric patients with upper respiratory symptoms.** Arch Otolaryngol Head Neck Surg. 2003;129:1213-20. (Level III evidence)
11. Yellon RF, Goldberg H. **Update on gastroesophageal reflux disease in pediatric airway disorders.** Am J Med. 2001;111:78S-84S. (Review article)
12. Contencin P, Gumpert LC, de Gaudemar I, Chaussain M, Dupont C. **Non-endoscopic techniques for evaluation of the pediatric airway.** Int J Pediatric Otorhinolaryngol. 1997;41:347-52. (Review article)
13. Beekman RP, Beek FJ, Hazekamp MG, Meijboom EJ. **The value of MRI in diagnosing vascular abnormalities causing stridor.** Eur J Pediatr. 1997;156:516-20. (Level III evidence). [View the reference](#)
14. Kussman BD, Geva R, McGowan FX. **Cardiovascular causes of airway compression.** Pediatr Anesth. 2004;14:60-74. (Review article)
15. Pacharn P, Poe SA, Donnelly LF. **Low-tube-current multidetector CT for children with suspected extrinsic airway compression.** AJR Am J Roentgenol. 2002;179:1523-7. (Level III evidence). [View the reference](#)
16. Rudman DT, Elmaraghy CA, Shiels WE, Wiet GJ. **The role of airway fluoroscopy in the evaluation of stridor in children.** Arch Otolaryngol Head Neck Surg. 2003;129:305-9. (Level III evidence)
17. John SD, Swischuk LE. **Stridor and upper airway obstruction in infants and children.** Radiographics. 1992;12:625-43. (Review article)



## Information for Consumers

Information from this website	Information from the Royal Australian and New Zealand College of Radiologists' website
<p><a href="#">Consent to Procedure or Treatment</a></p> <p><a href="#">Radiation Risks of X-rays and Scans</a></p> <p><a href="#">Computed Tomography (CT)</a></p> <p><a href="#">Magnetic Resonance Imaging (MRI)</a></p> <p><a href="#">Chest Radiograph (X-ray)</a></p> <p><a href="#">Plain Radiography (X-ray)</a></p>	<p><a href="#">Computed Tomography (CT)</a></p> <p><a href="#">Magnetic Resonance Imaging (MRI)</a></p> <p><a href="#">Plain Radiography/X-rays</a></p> <p><a href="#">Radiation Risk of Medical Imaging for Adults and Children</a></p> <p><a href="#">Children's (Paediatric) X-ray Examination</a></p> <p><a href="#">Making Your Child's Test or Procedure Less Stressful</a></p>

### Copyright

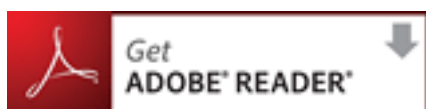© Copyright 2015, Department of Health Western Australia. All Rights Reserved. This web site and its content has been prepared by The Department of Health, Western Australia. The information contained on this web site is protected by copyright.

### Legal Notice

Please remember that this leaflet is intended as general information only. It is not definitive and The Department of Health, Western Australia can not accept any legal liability arising from its use. The information is kept as up to date and accurate as possible, but please be warned that it is always subject to change

### File Formats

Some documents for download on this website are in a Portable Document Format (PDF). To read these files you might need to download Adobe Acrobat Reader.



### [Legal Matters](#)