

Diagnostic Imaging Pathways - Vertigo

Population Covered By The Guidance

This pathway provides guidance on the imaging of adult patients with recent onset of vertigo.

Date reviewed: July 2014

Date of next review: 2017/2018






Published: December 2014

Quick User Guide

Move the mouse cursor over the **PINK** text boxes inside the flow chart to bring up a pop up box with salient points.

Clicking on the **PINK** text box will bring up the full text.

The relative radiation level (RRL) of each imaging investigation is displayed in the pop up box.

SYMBOL	RRL	EFFECTIVE DOSE RANGE
	None	0
	Minimal	< 1 millisieverts
	Low	1-5 mSv
	Medium	5-10 mSv
	High	>10 mSv

Pathway Diagram

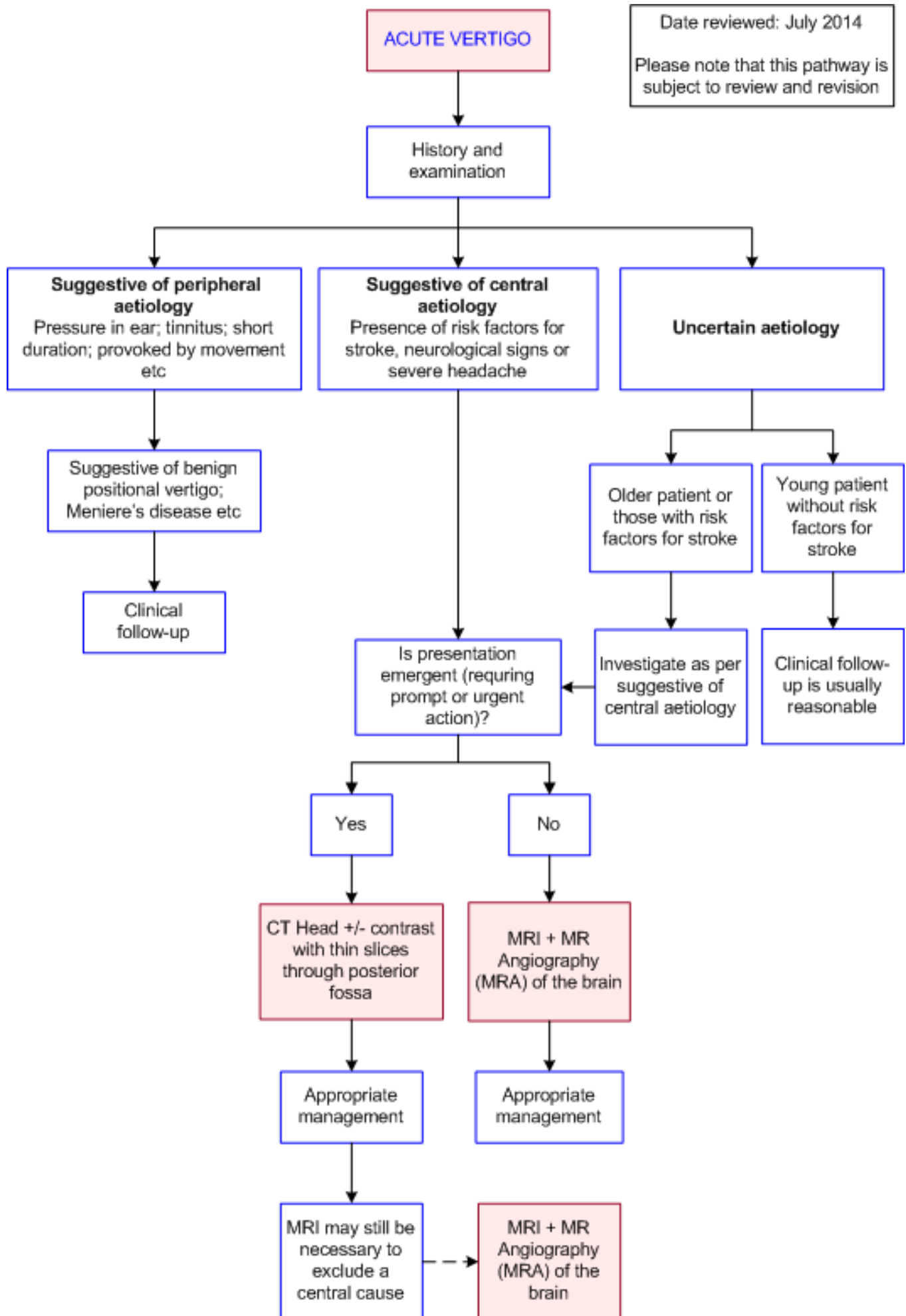
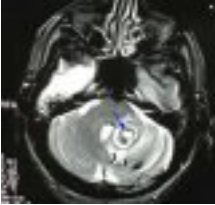


Image Gallery

Note: These images open in a new page

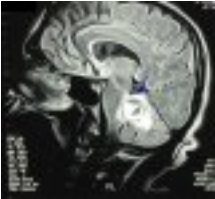1a



Cavernous Haemangioma

Image 1a and 1b (Magnetic Resonance Imaging): Axial and sagittal images demonstrating a cavernous haemangioma in the left cerebellar hemisphere extending towards the vermis. Surrounding high signal intensity indicates oedema.

1b



Teaching Points

- Vertigo is a symptom of illusory movement arising from damage or dysfunction of the vestibular system
- A history and detailed neurological examination is important to determine whether the symptoms and signs are suggestive of a peripheral or central cause of vertigo. This will dictate the need for and timing of the imaging
- MRI +/- MRA is generally indicated if a central cause of vertigo is suspected
- If MRI is unavailable or likely to be delayed, a CT scan with fine images of the posterior fossa is a suitable substitute

Magnetic Resonance Imaging (MRI) and Magnetic Resonance Angiography (MRA)

- Investigation of choice after clinical examination if [11](#)
 - A central cause for vertigo is suspected (e.g. vertebrobasilar system infarction, intracranial haemorrhage, neoplasm, multiple sclerosis or infection)
 - A central/peripheral distinction cannot be made and there are risk factors for stroke (e.g. hypertension, diabetes, smoking, atrial fibrillation, valvular heart disease) or a severe headache accompanying the vertigo [12](#)
- MRI has a higher diagnostic yield than CT in detecting central causes of vertigo
- MRI has a high sensitivity for the detection of cerebellar infarction, even early in the course of symptoms but may be less sensitive for the detection of a cerebellar haemorrhage. The conversion of oxyhaemoglobin to deoxyhaemoglobin, which may take 12-24 hours, also allows the more ready detection of haemorrhage [13](#)
- One study showed MRA to have a sensitivity of 97% and specificity of 98.9% for the diagnosis of occlusions and stenoses of the posterior circulation when compared to the reference standard of

intra-arterial angiography [14](#)

- The use of diffusion weighted imaging (DWI) is particularly useful for the detection of ischaemia. Two studies have shown DWI to have a sensitivity of 88-100% and specificity of 95-100% for the detection of ischaemia within 6 hours of stroke [15,16](#)
- Caution should be taken in patients with acute vestibular syndrome and suspected ischemic stroke and early negative MRI-DWIs within the first 48 hours when there is a higher false negative rate. [2, 6](#) A delayed MRI-DWI may be necessary
- Follow-up MRI can identify stroke missed on CT and in one study changed diagnosis 16% of the time [17](#)
- In a 2009 systematic review, Acoustic neuroma [18](#) was recommended to be imaged with MRI as the initial investigation of choice

Vertigo

- Vertigo and dizziness are a common emergent presentation and mostly related to peripheral (end organ vestibular) causes which are generally benign. A small proportion are due to central causes (e.g. posterior fossa haemorrhage of infarction) which if missed could lead to significant morbidity and mortality. [1](#)
- History and detailed neurological examination is important in distinguishing between central and peripheral aetiology and will inform subsequent diagnostic evaluation and treatment.
- The clinical decision rule (3 component bedside oculomotor examination), HINTS (horizontal head impulse test, nystagmus type and test of skew) and the risk stratification tool, ABCD2 risk score (age, blood pressure, clinical features, diabetes) are useful in determining the risk of stroke. [2-5](#)
- On systematic review HINTS was highly sensitive and specific in identifying stroke in patients with acute vestibular system and in the first 48hours was more effective in ruling out stroke than early MRI-DWI [6](#)
- Patients with vertigo have a 3 fold higher risk of stroke than the normal population; when they have at least 3 risk factors this increases to 5 fold. [7,8](#)
- Focal neurological deficit, age ≥ 60 or a chief complaint of imbalance have been associated with a serious underlying neurologic diagnosis. [9,10](#)
- Vertigo associated with ischaemia is typically of abrupt onset and occurs in patients with risk factors for stroke such as hypertension, diabetes, smoking or those with cardiac abnormalities such as atrial fibrillation or valvular heart disease. [21-25](#)

Computed Tomography (CT) of the Head

- Head CT is frequently used in emergent presentations where timely MRI is not available, impractical or contraindicated to exclude posterior fossa haemorrhage or a large mass as a cause for vertigo [17](#)
- It is less sensitive in detecting posterior fossa pathology and an ischemic stroke compared to MRI-DWI, has a lower diagnostic yield, and is associated with ionising radiation [10,15,17,19,20](#)
- CT is less sensitive for posterior fossa pathology and ischemic strokes (26% compared to 83% for MRI), a common cause of central vertigo. MRI is more appropriate but expensive and not readily available
- Fine cuts through the cerebellum should be used to assist with diagnosis. If immediate brain imaging is indicated and a normal CT is obtained on the first day subsequent MRI and MRA are generally recommended. In the meantime the patient's neurological status should be closely monitored [11](#)

- Imaging may not be necessary if the patient has isolated vertigo, no other neurological signs and no risk factors for stroke [11](#)

References

Date of literature search: June 2014

The search methodology is available on request. [Email](#)

References are graded from Level I to V according to the Oxford Centre for Evidence-Based Medicine, Levels of Evidence. [Download the document](#)

1. Navi BB, Kamel H, Shah MP, Grossman AW, Wong C, Poisson SN, et al. **The use of neuroimaging studies and neurological consultation to evaluate dizzy patients in the emergency department.** Neurohospitalist. 2013;3(1):7-14. (Level III evidence)
2. Newman-Toker DE, Kerber KA, Hsieh YH, Pula JH, Omron R, Saber Tehrani AS, et al. **HINTS Outperforms ABCD2 to Screen for Stroke in Acute Continuous Vertigo and Dizziness.** Acad Emerg Med. 2013;20(10):986-996. (Level II evidence)
3. Navi BB, Kamel H, Shah MP, Grossman AW, Wong C, Poisson SN, et al. **Application of the ABCD2 score to identify cerebrovascular causes of dizziness in the emergency department.** Stroke. 2012;43(6):1484-9. (Level III evidence)
4. Chen L, Lee W, Chambers BR, Dewey HM. **Diagnostic accuracy of acute vestibular syndrome at the bedside in a stroke unit.** J Neurol. 2011;258(5):855-61. (Level III evidence)
5. Kattah JC, Talkad AV, Wang DZ, Hsieh YH, Newman-Toker DE. **HINTS to diagnose stroke in the acute vestibular syndrome: three-step bedside oculomotor examination more sensitive than early MRI diffusion-weighted imaging.** Stroke. 2009;40(11):3504-10. (Level II evidence)
6. Tarnutzer AA, Berkowitz AL, Robinson KA, Hsieh YH, Newman-Toker DE. **Does my dizzy patient have a stroke? A systematic review of bedside diagnosis in acute vestibular syndrome.** CMAJ. 2011;183(9):E571-92. (Level I evidence)
7. Lee CC, Su YC, Ho HC, Hung SK, Lee MS, Chou P, et al. **Risk of stroke in patients hospitalized for isolated vertigo: a four-year follow-up study.** Stroke. 2011;42(1):48-52. (Level II evidence)
8. Choi K-D, Lee H, Kim J-S. **Vertigo in brainstem and cerebellar strokes.** Curr Opin Neurol. 2013;26(1):90-95. (Review article)
9. Navi BB, Kamel H, Shah MP, Grossman AW, Wong C, Poisson SN, et al. **Rate and predictors of serious neurologic causes of dizziness in the emergency department.** Mayo Clin Proc. 2012 ;87(11):1080-8. (Level III evidence)
10. Chase M, Joyce NR, Carney E, Saliccioli JD, Vinton D, Donnino MW, et al. **ED patients with vertigo: can we identify clinical factors associated with acute stroke?** Am J Emerg Med. 2012;30(4):587-91. (Level III evidence)
11. Guntinas-Lichius O. **Acute vestibular syndrome.** N Engl J Med. 1999;340(2):151-2. (Review article)
12. Moubayed SP, Saliba I. **Vertebrobasilar insufficiency presenting as isolated positional vertigo or dizziness: a double-blind retrospective cohort study.** Laryngoscope. 2009;119(10):2071-6. (Level II evidence)
13. Bradley WG, Jr. **MR appearance of hemorrhage in the brain.** Radiology. 1993;189(1):15-26. (Review article)
14. Rother J, Wentz KU, Rautenberg W, Schwartz A, Hennerici M. **Magnetic resonance angiography in vertebrobasilar ischemia.** Stroke. 1993;24(9):1310-5. (Level II evidence)
15. Gonzalez RG, Schaefer PW, Buonanno FS, Schwamm LH, Budzik RF, Rordorf G, et al. **Diffusion-weighted MR imaging: diagnostic accuracy in patients imaged within 6 hours of stroke**



- symptom onset.** Radiology. 1999;210(1):155-62. (Level III evidence)
16. Lovblad KO, Laubach HJ, Baird AE, Curtin F, Schlaug G, Edelman RR, et al. **Clinical experience with diffusion-weighted MR in patients with acute stroke.** AJNR Am J Neuroradiol. 1998;19(6):1061-6. (Level III evidence)
 17. Lawhn-Heath C, Buckle C, Christoforidis G, Straus C. **Utility of head CT in the evaluation of vertigo/dizziness in the emergency department.** Emerg Radiol. 2013;20(1):45-9. (Level III evidence)
 18. Fortnum H, O'Neill C, Taylor R, Lenthall R, Nikolopoulos T, Lightfoot G, et al. **The role of magnetic resonance imaging in the identification of suspected acoustic neuroma: a systematic review of clinical and cost effectiveness and natural history.** Health Technol Assess. 2009;13(18):iii-iv, ix-xi, 1-154. (Level I evidence)
 19. Ahsan SF, Syamal MN, Yaremchuk K, Peterson E, Seidman M. **The costs and utility of imaging in evaluating dizzy patients in the emergency room.** Laryngoscope. 2013;123(9):2250-3. (Level III evidence)
 20. Fiebach JB, Schellinger PD, Jansen O, Meyer M, Wilde P, Bender J, et al. **CT and diffusion-weighted MR imaging in randomized order: diffusion-weighted imaging results in higher accuracy and lower interrater variability in the diagnosis of hyperacute ischemic stroke.** Stroke. 2002;33(9):2206-10. (Level II evidence)
 21. Oas JG, Baloh RW. **Vertigo and the anterior inferior cerebellar artery syndrome.** Neurology. 1992;42(12):2274-9. (Level IV evidence)
 22. Amarenco P, Levy C, Cohen A, Touboul PJ, Roullet E, Bousser MG. **Causes and mechanisms of territorial and nonterritorial cerebellar infarcts in 115 consecutive patients.** Stroke. 1994;25(1):105-12. (Level III evidence)
 23. Grad A, Baloh RW. **Vertigo of vascular origin. Clinical and electronystagmographic features in 84 cases.** Arch Neurol. 1989;46(3):281-4. (Level IV evidence)
 24. Gomez CR, Cruz-Flores S, Malkoff MD, Sauer CM, Burch CM. **Isolated vertigo as a manifestation of vertebrobasilar ischemia.** Neurology. 1996;47(1):94-7. (Level III evidence)
 25. Norrving B, Magnusson M, Holtas S. **Isolated acute vertigo in the elderly; vestibular or vascular disease?** Acta Neurol Scand. 1995;91(1):43-8. (Level II/III evidence)
 26. Lee W, Chen L, Waterston J. **Vertebrobasilar ischaemia presenting as recurrent isolated vertigo.** Acta Otolaryngol. 2011;131(8):887-9. (Level IV evidence)

Information for Consumers

Information from this website	Information from the Royal Australian and New Zealand College of Radiologists' website
Consent to Procedure or Treatment Radiation Risks of X-rays and Scans Computed Tomography (CT) Computed Tomography (CT) Angiography Magnetic Resonance Angiography (MRA)	Angiography Computed Tomography (CT) Contrast Medium (Gadolinium versus Iodine) Gadolinium Contrast Medium

[Magnetic Resonance Imaging \(MRI\)](#)

[Iodine-Containing Contrast Medium](#)

[Magnetic Resonance Imaging \(MRI\)](#)

[Plain Radiography/X-rays](#)

[Radiation Risk of Medical Imaging During
Pregnancy](#)

[Radiation Risk of Medical Imaging for
Adults and Children](#)

Copyright

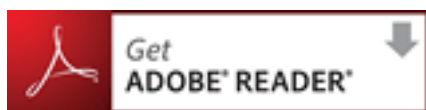
© Copyright 2015, Department of Health Western Australia. All Rights Reserved. This web site and its content has been prepared by The Department of Health, Western Australia. The information contained on this web site is protected by copyright.

Legal Notice

Please remember that this leaflet is intended as general information only. It is not definitive and The Department of Health, Western Australia can not accept any legal liability arising from its use. The information is kept as up to date and accurate as possible, but please be warned that it is always subject to change

File Formats

Some documents for download on this website are in a Portable Document Format (PDF). To read these files you might need to download Adobe Acrobat Reader.



[Legal Matters](#)