

# Diagnostic Imaging Pathways - Foot Ulcer (Diabetic)

## Population Covered By The Guidance

This pathway provides guidance on the imaging of diabetic patients with diabetic foot ulcers.

**Date reviewed: August 2013**

**Date of next review: 2017/2018**






**Published: August 2013**

### Quick User Guide

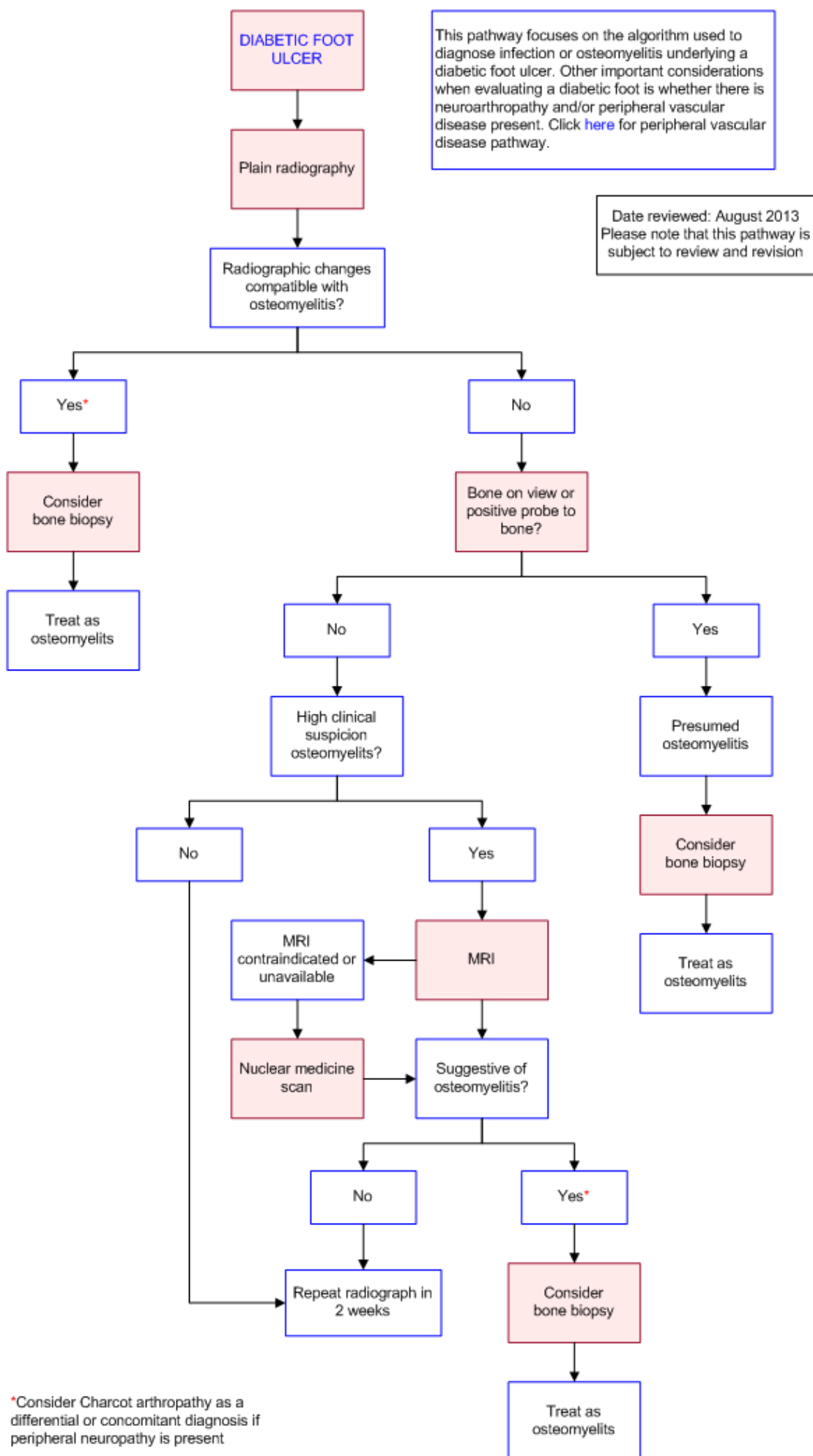
Move the mouse cursor over the **PINK** text boxes inside the flow chart to bring up a pop up box with salient points.

Clicking on the **PINK** text box will bring up the full text.

The relative radiation level (RRL) of each imaging investigation is displayed in the pop up box.

SYMBOL	RRL	EFFECTIVE DOSE RANGE
	None	0
	Minimal	< 1 millisieverts
	Low	1-5 mSv
	Medium	5-10 mSv
	High	>10 mSv

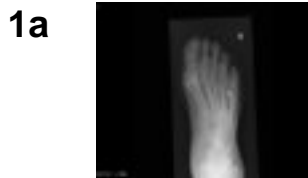## Pathway Diagram



\*Consider Charcot arthropathy as a differential or concomitant diagnosis if peripheral neuropathy is present

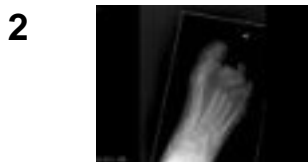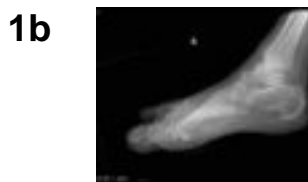## Image Gallery

*Note: These images open in a new page*



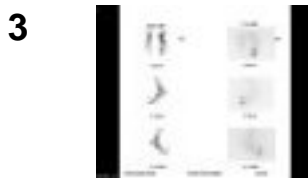
### Diabetic Foot Osteomyelitis

**Image 1a and 1b (Plain Radiography):** DP and lateral views of a foot showing cortical erosion of the 4th metatarsal head in keeping with osteomyelitis (arrow). There is a small gas locule in the soft tissue between the 4th and 5th metatarsal heads which could indicate a gas forming organism causing an abscess (arrowhead).



### Diabetic Foot Osteomyelitis

**Image 2 (Plain Radiography):** Extensive destructive changes consistent with a pyogenic infection which involves the IP joint of the great toe, all phalanges of the 2nd toe and 2nd MTP joint, all phalanges of the 3rd toe and 3rd MTP joint, proximal phalanx of the 4th toe and 4th MTP joint.



### Diabetic Foot Osteomyelitis

**Image 3 (Radionuclide Scan):** Dual bone/white cell study (Tc-99 MBP/In-111 WBC). Delayed bone scan demonstrates intense focal uptake in the medial aspect of the proximal part of the distal phalanx of the right 1st toe. White cell study demonstrates intense focal uptake corresponding to the medial aspect of the proximal part of the distal phalanx of the right 1st toe. This scintigraphic appearance is consistent with osteomyelitis.

There is also focal intense uptake on bone scan in the inferior aspect of the calcaneo-cuboidal junction, which is not demonstrated on white cell study. This may represent neuroarthropathy or tendonitis.

- **Diabetic foot complications are the most common cause for non-traumatic lower limb amputation [1-4](#)**
- **An estimated 15% of patients with diabetes will develop a foot ulcer during the course of their disease, with 85% of diabetes related lower limb amputations preceded by a foot ulcer [5,6](#)**
- **Foot disorders are the most common diabetic complication requiring hospitalisation, and are associated with the longest length of stay [6](#)**
- **Approximately 20% of diabetic inpatients will have foot related complications which require acute care and/or management [1,3](#)**
- **Osteomyelitis in the diabetic foot generally occurs by the direct extension of infection from underlying soft tissue ulcers, with bacteria penetrating cortical bone to access the marrow cavity**
- **Osteomyelitis is a diagnostic challenge, and imaging is commonly utilised**
- **The presence of osteomyelitis increases the risk of amputation [1,4,7](#)**

## Clinical Findings

- **The signs and symptoms of infection may be absent or masked by the coexistence of vascular disease or neuropathy [1](#)**
- **Clinical evaluation should include an assessment of the patient's diabetes**
- **The physical examination and laboratory findings which have shown to be likelihood of osteomyelitis include**
  - **Bone exposure – direct visualisation of bone or the ability to probe the base of the wound to bone. Depending on prevalence (sensitivity 38-87%; specificity 85-91%; positive likelihood ratio 6.4; negative LR 0.39) [8-10](#)**
  - **Ulcer area larger than 2cm<sup>2</sup> (sensitivity 56%; specificity 92%) [2](#)**
  - **Deep (>3mm depth) ulcer (sensitivity 74%, specificity 77%) [2](#)**
  - **ESR >70mm/h (sensitivity 90%; specificity 100%) [11](#)**
  - **ALP >135U/L (specificity 100%) [2](#)**
  - **"Sausage toe" appearance (i.e. red swollen digit) in instances of toe ulceration [12](#)**
- **Factors that did not modify the probability of osteomyelitis**
  - **Presence or absence of ulcer inflammation [2](#)**
  - **Elevated white blood cell count, regardless of cut off applied [13](#)**
  - **Result of swab culture [14](#)**

## Plain Radiography

- **Initial procedure for imaging suspected osteomyelitis in the diabetic patient [15](#)**
- **Evidence of progression or resolution may be used to monitor response to antibiotic treatment**

- **Characteristic signs of osteomyelitis on plain radiograph include cortical erosion, periosteal reaction, mixed lucency and sclerosis** [15](#)
- **Pooled sensitivity of 54% and specificity of 68% for osteomyelitis on recent meta-analysis** [16](#)
- **Sensitivity is limited as radiological changes are delayed for up to four weeks following infection. Typically radiographs don't show abnormalities until about two weeks after initial infection, when nearly 50% of the bone mineral content has been lost** [15,17](#)
- **Specificity is limited by difficulty differentiating infection from neuro-osteoarthropathy in a patient with bony destruction (Charcot's arthropathy)** [15](#)
- **Plain radiographs can also reveal presence of radio-opaque foreign bodies, gas in soft tissues, calcified arteries fractures or bony abnormalities** [3,15](#)
- **Normal plain radiographs do not exclude osteomyelitis. An abnormal plain radiographs doubles the odds of osteomyelitis based on a limited systematic review** [1](#)

## Magnetic Resonance Imaging (MRI)

- **Preferred advanced imaging modality for diagnosing osteomyelitis** [15](#)
- **Two metaanalyses reported similar pooled sensitivities of 90% (range 77-100%) and specificities of 79-82.5% (range 40-100%) in the diagnosis of foot osteomyelitis, outperforming plain radiography, <sup>99m</sup>Tc bone scanning and leucocyte scintigraphy** [16,18](#)
- **Advantages**
  - **No ionising radiation**
  - **Optimal visualisation of soft tissue structures, including detection of sinus tracts, deep tissue necrosis, abscesses and other inflammatory changes** [15](#)
  - **High sensitivity in early stages - reveals bony oedema useful for early detection of infection**

## Nuclear Medicine Scans

- **Nuclear imaging scans are more sensitive than radiographs for detecting osteomyelitis during early stages of the disease, however they have poor specificity and abnormalities are slow to resolve**
- **Focal hyperperfusion, hyperaemia and bony uptake on delayed images are signs of osteomyelitis on bone scan. These signs may also be seen in other conditions such as fracture, neuroarthropathy and chronic soft tissue infection** [6,19](#)
- **Three phase technetium bone scan (Tc-99 MDP) has been reported on recent**



**meta-analyses to be sensitive (80-90% but not specific (28-46%) for osteomyelitis, indicating poor discriminating ability. [16,19](#) The diagnostic performance was markedly inferior to MRI (diagnostic odds ratio 3.5 versus 150) [18](#)**

- **Labelled leucocyte scintigraphy with either indium-111 ( $^{111}\text{In}$ ) or technetium-99 ( $^{99\text{m}}\text{Tc}$ ), improves specificity (to 74 and 85% respectively) for diagnosing acute infections [19](#)**
- **A combined dual study of Tc-99 MDP and labelled leucocyte scintigraphy (Indium-111) may improve sensitivity and specificity [6,20](#)**
- **Recent data suggest a role for FDG-PET/CT or SPECT/CT with bone and leukocyte scanning but the utility and cost effectiveness of this approach requires further study and is currently not recommended routinely by expert guidelines [15,21](#)**
- **Where MRI is unavailable or contraindicated, a radionuclide bone scan and a labelled white blood cell scan is recommended as the best alternative to rule out osteomyelitis [15](#) A negative bone scan effectively excludes osteomyelitis**

## Bone Biopsy

- **The gold standard for diagnosis of osteomyelitis [15](#)**
- **Bone biopsy has a role not only in the diagnosis of osteomyelitis, but also the isolation of causative pathogen(s) and their antibiotic sensitivities to guide therapy**
- **Bone biopsy is performed under sterile conditions either during surgical debridement or percutaneously through uninvolved skin under fluoroscopic or CT guidance [7](#)**
- **Ideally bone specimens should be sent for both histopathology and microbiology [1,7,22](#)**
- **Diagnosis of osteomyelitis is based on isolation of bacteria and findings of osteonecrosis and infiltration of the bone with inflammatory cells on histopathology [7](#)**
- **Superficial swab culture does not reliably predict the bacteria causing osteomyelitis. Swab culture identified the identical pathogen as bone culture in only 22.5% of isolates [23](#)**
- **Disadvantages of bone biopsy include cost, availability of equipment and expertise, interference by antibiotics in culture results and potential for sampling error (false negative), contamination (false positive), invasiveness of the procedure and patient discomfort**
- **Bone biopsy should be avoided in patients with advanced vascular disease as the incision for bone biopsy may not heal [1,2](#)**
- **There have been no published reports of complications associated with bone biopsy of the foot [7](#)**

## References

Date of literature search: April 2013

The search methodology is available on request. [Email](#)

References are graded from Level I to V according to the Oxford Centre for Evidence-Based Medicine, Levels of Evidence. [Download the document](#)

1. Butalia S, Palda VA, Sargeant RJ, Detsky AS, Mourad O. Does this patient with diabetes have osteomyelitis of the lower extremity? *JAMA*. 2008;299(7):806-13. (Level II evidence)
2. Newman LG, Waller J, Palestro CJ, Schwartz M, Klein MJ, Hermann G, et al. Unsuspected osteomyelitis in diabetic foot ulcers. Diagnosis and monitoring by leukocyte scanning with indium in 111 oxyquinoline. *JAMA*. 1991;266(9):1246-51. (Level II evidence)
3. Wraight PR, Lawrence SM, Campbell DA, Colman PG. Creation of a multidisciplinary, evidence based, clinical guideline for the assessment, investigation and management of acute diabetes related foot complications. *Diabet Med*. 2005;22(2):127-36. (Evidence based guideline)
4. Ertugrul MB, Baktiroglu S, Salman S, Unal S, Aksoy M, Berberoglu K, et al. The diagnosis of osteomyelitis of the foot in diabetes: microbiological examination vs. magnetic resonance imaging and labelled leucocyte scanning. *Diabet Med*. 2006;23(6):649-53. (Level II evidence)
5. Margolis D, Allen Taylor L, Hoffstad O, Berlin J. Diabetic neuropathic foot ulcers and amputation. *Wound Repair Regen*. 2005;13(3):230-6. (Level II evidence)
6. Frykberg RG, Zgonis T, Armstrong DG, Driver VR, Giurini JM, Kravitz SR, et al. Diabetic foot disorders: a clinical practice guideline (2006 revision). *J Foot Ankle Surg*. 2006;45(5,Supplement):S1-66. (Review article)
7. Lipsky BA, Berendt AR, Deery HG, Embil JM, Joseph WS, Karchmer AW, et al. Diagnosis and treatment of diabetic foot infections. *Clin Infect Dis*. 2004;39(7):885-910. (Review article)
8. Grayson ML, Gibbons GW, Balogh K, Levin E, Karchmer AW. Probing to bone in infected pedal ulcers. A clinical sign of underlying osteomyelitis in diabetic patients. *JAMA*. 1995;273(9):721-3. (Level III evidence)
9. Lavery L, Armstrong D, Peters EJG, Lipsky B. Probe-to-bone test for diagnosing diabetic foot osteomyelitis: reliable or relic? *Diabetes Care*. 2007;30(2):270-4. (Level IV evidence)
10. Shone A, Burnside J, Chipchase S, Game F, Jeffcoate W. Probing the validity of the probe-to-bone test in the diagnosis of osteomyelitis of the foot in diabetes. *Diabetes Care*. 2006;29(4):945. (Level III evidence)
11. Kaleta JL, Fleischli JW, Reilly CH. The diagnosis of osteomyelitis in diabetes using erythrocyte sedimentation rate: a pilot study. *J Am Podiatr Med Assoc*.

- 2001;91(9):445-50. (Level IV evidence)**
- 12. Rajbhandari SM, Sutton M, Davies C, Tesfaye S, Ward JD. 'Sausage toe': a reliable sign of underlying osteomyelitis. *Diabet Med.* 2000;17(1):74-7. (Level III evidence)**
  - 13. Armstrong DG, Lavery LA, Sariaya M, Ashry H. Leukocytosis is a poor indicator of acute osteomyelitis of the foot in diabetes mellitus. *J Foot Ankle Surg.* 1996;35(4):280-3. (Level IV evidence)**
  - 14. Oyen WJ, Netten PM, Lemmens JA, Claessens RA, Lutterman JA, van der Vliet JA, et al. Evaluation of infectious diabetic foot complications with indium-111-labeled human nonspecific immunoglobulin G. *J Nucl Med.* 1992;33(7):1330-6. (Level IV evidence)**
  - 15. Lipsky BA, Berendt AR, Cornia PB, Pile JC, Peters EJ, Armstrong DG, et al. 2012 Infectious Diseases Society of America clinical practice guideline for the diagnosis and treatment of diabetic foot infections. *Clin Infect Dis.* 2012;54(12):e132-73. (Evidence based guideline)**
  - 16. Dinh MT, Abad CL, Safdar N. Diagnostic accuracy of the physical examination and imaging tests for osteomyelitis underlying diabetic foot ulcers: meta-analysis. *Clin Infect Dis.* 2008;47(4):519-27. (Level I evidence)**
  - 17. Pineda C, Espinosa R, Pena A. Radiographic imaging in osteomyelitis: the role of plain radiography, computed tomography, ultrasonography, magnetic resonance imaging, and scintigraphy. *Semin Plastic Surg.* 2009;23(2):80-9. (Review article)**
  - 18. Kapoor A, Page S, LaValley M, Gale D. R, Felson D. T. Magnetic resonance imaging for diagnosing foot osteomyelitis: A meta-analysis. *Arch Intern Med.* 2007;167(2):125-32. (Level II evidence)**
  - 19. Capriotti G, Chianelli M, Signore A. Nuclear medicine imaging of diabetic foot infection: results of meta-analysis. *Nucl Med Commun.* 2006;27(10):757-64. (Level II evidence)**
  - 20. Termaat MF, Raijmakers PGHM, Scholten HJ, Bakker FC, Patka P, Haarman HJTM. The accuracy of diagnostic imaging for the assessment of chronic osteomyelitis: a systematic review and meta-analysis. *J Bone Joint Surg Am.* 2005;87(11):2464-71. (Level I/II evidence)**
  - 21. Nawaz A, Torigian DA, Siegelman ES, Basu S, Chryssikos T, Alavi A. Diagnostic performance of FDG-PET, MRI, and plain film radiography (PFR) for the diagnosis of osteomyelitis in the diabetic foot. *Molecular Imaging and Biology : MIB.* 2010;12(3):335-42. Available from: ProQuest Central; ProQuest Health & Medical Complete; ProQuest Nursing & Allied Health Source. (Level II evidence)**
  - 22. White LM, Schweitzer ME, Deely DM, Gannon F. Study of osteomyelitis: utility of combined histologic and microbiologic evaluation of percutaneous biopsy samples. *Radiology.* 1995;197(3):840-2. (Level III evidence)**
  - 23. Senneville E, Melliez H, Beltrand E, Legout L, Valette M, Cazaubie M, et al. Culture of percutaneous bone biopsy specimens for diagnosis of diabetic foot osteomyelitis: concordance with ulcer swab cultures. *Clin Infect Dis.***





**2006;42(1):57-62. (Level II evidence)**

## Information for Consumers

Information from this website	Information from the Royal Australian and New Zealand College of Radiologists' website
<p><a href="#">Consent to Procedure or Treatment</a></p> <p><a href="#">Radiation Risks of X-rays and Scans</a></p> <p><a href="#">Bone Scan</a></p> <p><a href="#">Magnetic Resonance Imaging (MRI)</a></p> <p><a href="#">Positron Emission Tomography (PET)</a></p> <p><a href="#">Plain Radiography (X-ray)</a></p>	<p><a href="#">Gadolinium Contrast Medium</a></p> <p><a href="#">Iodine-Containing Contrast Medium</a></p> <p><a href="#">Magnetic Resonance Imaging (MRI)</a></p> <p><a href="#">Plain Radiography/X-rays</a></p> <p><a href="#">Radiation Risk of Medical Imaging During Pregnancy</a></p> <p><a href="#">Radiation Risk of Medical Imaging for Adults and Children</a></p> <p><a href="#">Nuclear Medicine</a></p> <p><a href="#">Nuclear Medicine Bone Scan</a></p>

## Copyright

© Copyright 2015, Department of Health Western Australia. All Rights Reserved. This web site and its content has been prepared by The Department of Health, Western Australia. The information contained on this web site is protected by copyright.

## Legal Notice

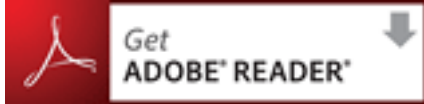Please remember that this leaflet is intended as general information only. It is not definitive and The Department of Health, Western Australia can not accept any legal

**liability arising from its use. The information is kept as up to date and accurate as possible, but please be warned that it is always subject to change**

.

## **File Formats**

**Some documents for download on this website are in a Portable Document Format (PDF). To read these files you might need to download Adobe Acrobat Reader.**



[Legal Matters](#)