

Diagnostic Imaging Pathways - Colorectal Cancer (Staging)

Population Covered By The Guidance

This pathway provides guidance on imaging patients with proven colorectal cancer, indicating how imaging helps determine management.

Date reviewed: January 2012

Date of next review: 2017/2018

Published: January 2012

Quick User Guide

Move the mouse cursor over the **PINK** text boxes inside the flow chart to bring up a pop up box with salient points.

Clicking on the **PINK** text box will bring up the full text.

The relative radiation level (RRL) of each imaging investigation is displayed in the pop up box.

SYMBOL	RRL	EFFECTIVE DOSE RANGE
	None	0
	Minimal	< 1 millisieverts
	Low	1-5 mSv
	Medium	5-10 mSv
	High	>10 mSv

Pathway Diagram

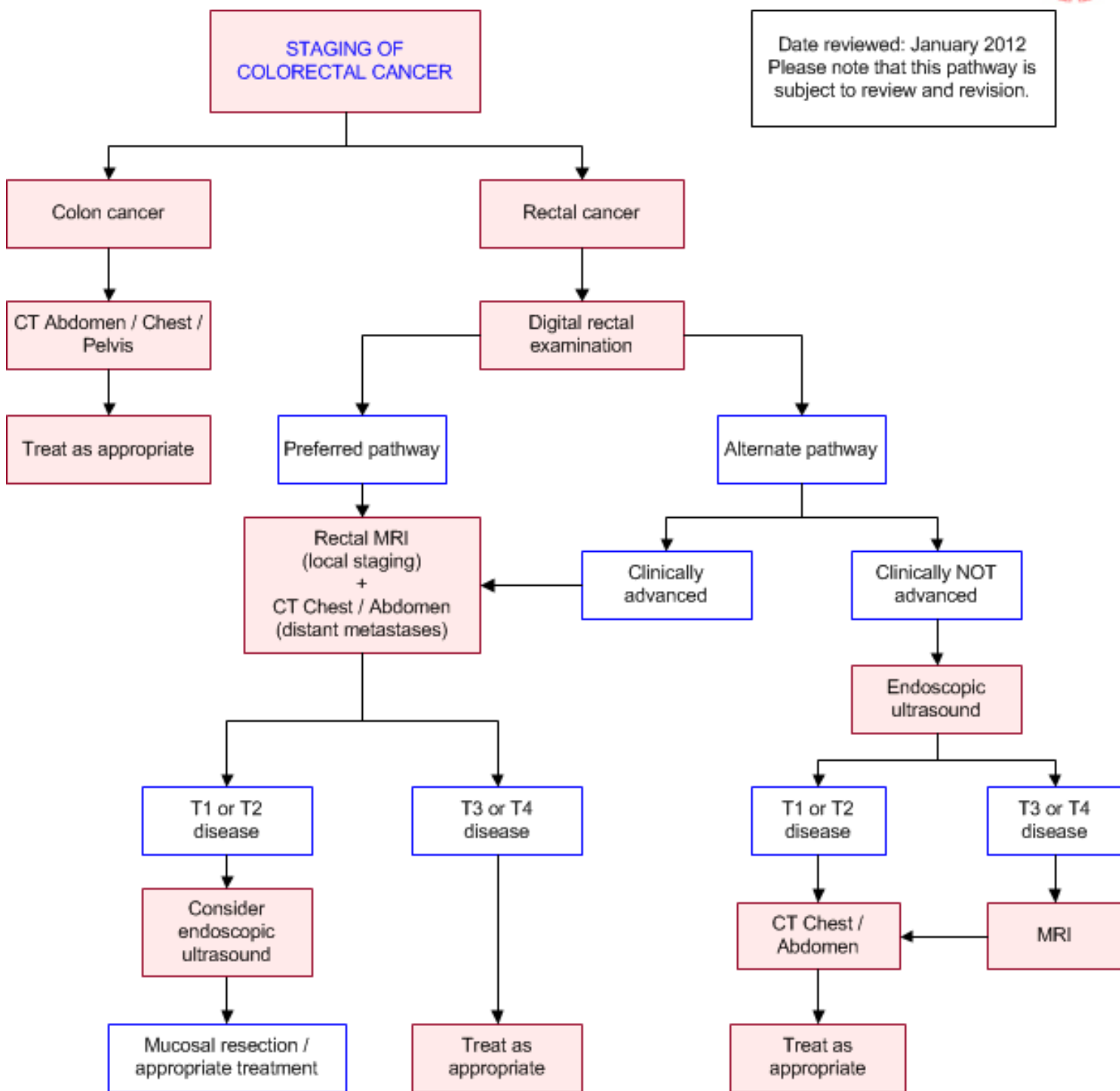
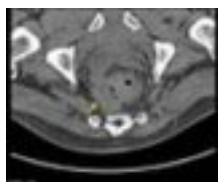


Image Gallery

Note: These images open in a new page

1



Rectal Carcinoma

Image 1 (Computed Tomography): Thickened rectal wall with invasion of the mesorectal fascia on the right side (arrow). The mesorectal fascia on the left

appears normal.

2 **Rectal Carcinoma**




Image 2 (Endorectal Ultrasound): Rectal carcinoma with infiltration into the perirectal fat (arrows) (T3 lesion).

3a **Colonic Carcinoma**

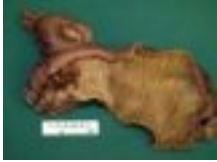
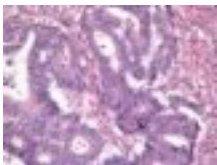
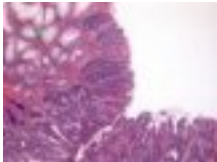Image 3a: Right hemicolectomy specimen showing a large ulcerated and exophytic caecal carcinoma.

3b **3c** Image 3b (H&E, x2.5) and 3c (H&E, x10): Histological sections showing a moderately differentiated colorectal adenocarcinoma composed of malignant glands invading into the bowel wall (blue arrows). The glands are lined by cells showing marked nuclear atypia. Normal colonic mucosa is included for comparison (green arrow).



Teaching Points

- The staging processes for colon cancer and rectal cancer are different
- In colon cancer, locoregional staging is often not indicated unless advanced disease is suspected. In this case, CT / ultrasound of the abdomen and chest radiography may be performed if surgical or management decisions are likely to change
- In rectal cancer accurate staging pre-operatively is essential, as chemo-radiotherapy has been shown to be effective in certain groups
 - Endorectal US and Pelvic MRI are complimentary investigations

Staging of Colon Cancer

- Surgery for colon cancer is not stage-dependent. The majority of patients with colon cancer will undergo surgical treatment whether with curative or palliative intent
- The purpose of preoperative imaging is to detect synchronous tumours, assess contiguous organ involvement and distant metastases. Generally this involves CT imaging of the chest, abdomen & pelvis
- Other preoperative workup includes physical examination and complete colonoscopy (or CT colonoscopy if the patient is unable to tolerate normal colonoscopy)
- A recent meta-analysis of CT imaging for colon cancer for local staging found that the sensitivity and specificity for T staging was 86% and 78% respectively and for N staging, 70% and 78% respectively. [44](#) CT is particularly useful for distinguishing advanced tumour invading beyond the muscularis propria (stage T3+). CT also has a high negative predictive value in clinically advanced disease [4,5,6](#)
- CT has 70-80% sensitivity for the detection of hepatic metastases [3,4](#)
- There is emerging evidence that CT is useful in aiding operative management and directly alters surgical management in a smaller number of cases. [8,9](#) Furthermore, CT has been used to

prognosticate patients into “favourable” and “poor” groups, based on radiological characteristics [10](#)

- There is no advantage of MRI over CT for local staging of tumour [2,7](#)
- Limitations: CT is less reliable for local staging because of low sensitivity for detection of local tumour extent and lymph node metastases [4,6,7](#)

Staging of Colorectal Cancer

- A careful pre-operative search for systemic metastases is rarely indicated in patients with colon cancer, as the initial management is often not altered. A CT scan of the abdomen should be considered, if there are clinical indications of a locally advanced cancer or systemic metastasis that may alter operative or management strategies [1](#)
- Pre-operative identification of liver/lung metastases may be useful in [1](#)
 - Frail, elderly patients who may not need resection of a relatively asymptomatic primary tumour
 - Patients with clinical indication of extensive local (>50%) liver metastases, as this carries a high operative morbidity and mortality
 - Identifying the few selected cases, where synchronous liver resection for metastatic disease may be performed concurrently at the time of bowel resection
- Preoperative locoregional staging of patients with rectal cancer is important, both to plan surgery and to consider the possible need for adjuvant chemoradiotherapy. [1](#) Careful attention to staging is required, as local recurrence (and hence prognosis) is dependant on accurate staging [2](#)

Computed Tomography (CT)

- In the setting of rectal cancer staging, Computed Tomography (CT) scans of the chest & abdomen are appropriate for the detection of metastatic disease
- Despite significant advances in CT technology (multi-detectors, helical scanning), CT is still relatively poor at differentiating the layers of the rectum and identifying tumour involvement of the circumferential resection margin (compared with MRI and EUS). A meta-analysis of imaging for rectal cancer staging found that EUS and MRI had better diagnostic accuracy than CT for T & N staging. [46](#) The sensitivity and specificity of CT for T-staging was 72-79% and 78-96% respectively. Hence, CT is not recommended as the primary imaging for local staging
- CT has been shown to be able to identify mesorectal lymph nodes as small as 5mm. Currently, anatomical size criteria are used as a surrogate measure of lymph node metastases. This is an inaccurate method since lymph nodes may be enlarged due to benign reasons (resulting in false positives) or there may be micrometastatic deposits on normal sized lymph nodes (resulting in false negatives). [47](#) Nodal staging with CT has a sensitivity and specificity of 55% and 74% respectively [46](#)
- CT can accurately stage distant metastases. Rectal cancer has a greater tendency for pulmonary spread compared to colon cancer (11.5% vs 3.5%). [48](#) Traditionally, chest radiography has been used to detect pulmonary metastases, but they can miss smaller nodules and nodules in shadowed areas (e.g. retro-cardiac space). In a recent prospective study, Choi et al. found that routine staging chest CT detected more lung metastases than chest radiography (9 vs 5 patients), and affected treatment in 3 of the 4 missed patients [48](#)

Digital Rectal Examination



- On the basis of fixity and presence of rectal tumour outside the rectal wall on DRE, it is possible to divide the lesion as 'locally not extensive' or 'locally extensive' [19](#)
- This will dictate the most appropriate initial investigation in locoregional staging of rectal cancer

Endorectal Ultrasound

- High accuracy (85 - 95%) in evaluation of tumour penetration and perirectal spread [20,21,35](#)
- Staging is most accurate for T1 and T2 cancers. [22,36](#) This may facilitate local excision of the carcinoma, if distant metastasis are absent on the staging CT of the abdomen
- It is as accurate as MRI and MDCT in the detection of local nodal disease [23](#)
- Limitations - it is less accurate in staging advanced tumours (especially in differentiating 'early' and 'late' T3 lesions) and is unable to visualise the mesorectal fascia. [2](#) It is also highly operator dependant, may not be able technically possible in high rectal cancers or a stenosing lesion and is limited by availability in some centres

Magnetic Resonance Imaging (MRI)

- Pelvic MRI is used widely for the staging and treatment planning of rectal cancer [43](#)
- MRI is superior to endorectal US for evaluation of the relationship of the tumour to the mesorectal fascia. [24,25](#) A meta-analysis has shown that MRI is the only modality that predicts the circumferential resection margin with good accuracy [23,37](#)
- This is important with the surgical technique of TME, as one of the strongest predictors for local recurrence is the least distance between tumour and the circumferential resection margin. MRI can accurately predict the distance between the tumour edge and the mesorectal fascia [25,26,27,38,39](#) Various trials have validated pelvic MRI in being able to predict resection margin, when compared to the gold standard of histology [28,29,40](#),