

Diagnostic Imaging Pathways - Gastric Cancer (Staging)

Population Covered By The Guidance

This pathway provides a staging algorithm for patients with proven gastric cancer, indicating how imaging helps determine management.

Date reviewed: March 2015

Date of next review: 2017/2018

Published: July 2015

Quick User Guide

Move the mouse cursor over the **PINK** text boxes inside the flow chart to bring up a pop up box with salient points.

Clicking on the **PINK** text box will bring up the full text.

The relative radiation level (RRL) of each imaging investigation is displayed in the pop up box.

SYMBOL	RRL	EFFECTIVE DOSE RANGE
	None	0
	Minimal	< 1 millisieverts
	Low	1-5 mSv
	Medium	5-10 mSv
	High	>10 mSv

Pathway Diagram

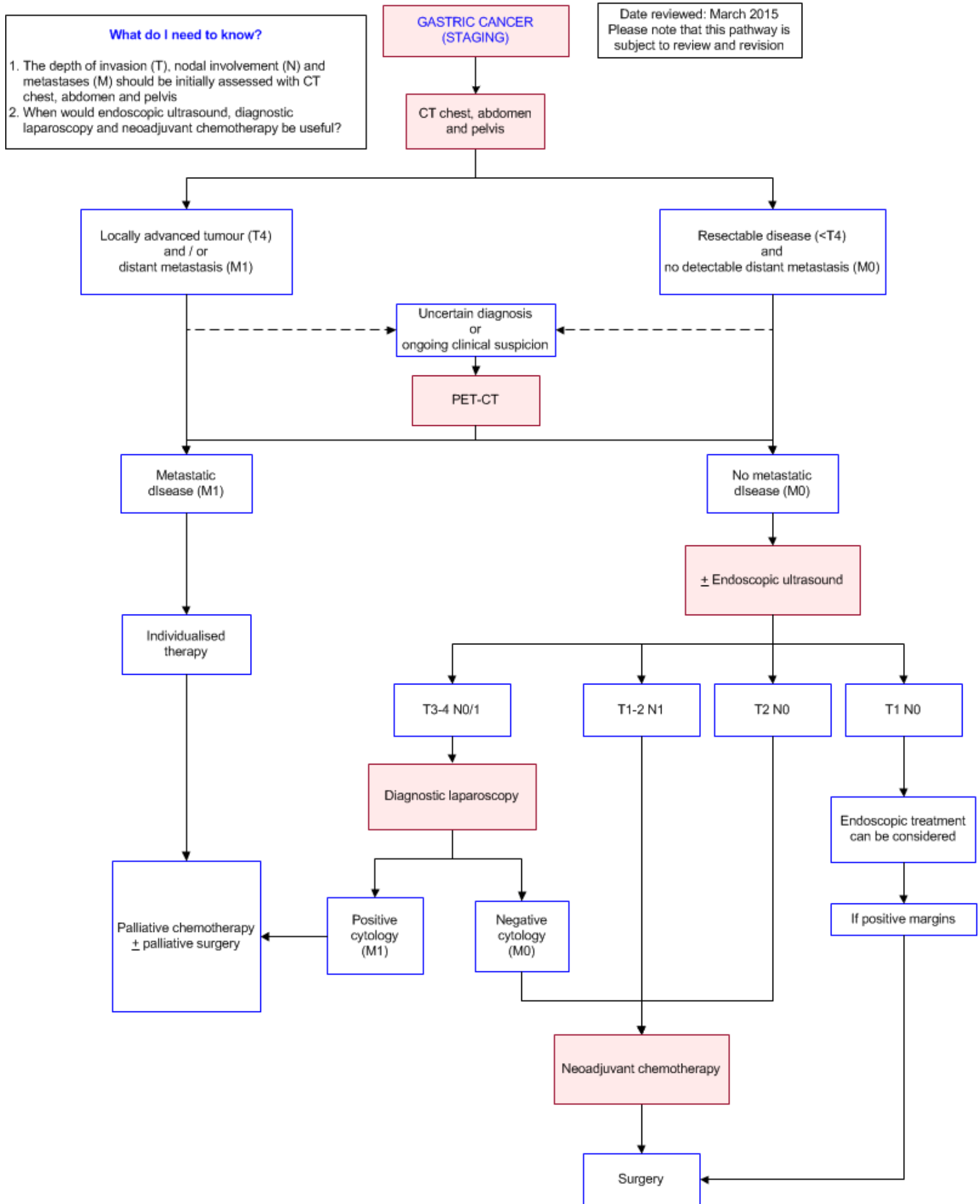


Image Gallery

There are currently no images on this page

Teaching Points

- Staging of gastric malignancy is aimed at assessing the extent of local invasion of the primary tumour and for the presence or absence of nodal / distal metastatic disease
- CT of the chest, abdomen and pelvis are suitable initial staging modalities
- If these initial investigations demonstrate a lesion that is amenable to potential curative resection, further staging should include a PET-CT scan
- If a PET-CT scan shows no distal metastatic disease, endoscopic ultrasound (EUS) is indicated for local staging in selected cases
- Diagnostic laparoscopy should be considered for locally advanced disease (?T3, N-any) when presumed metastases is not detected as peritoneal metastasis is often undetected on CT
- MRI has not been widely used in the past for the staging of gastric carcinoma mainly due to motion artefacts. Introduction of various changes has seen image quality improvement. In more recent studies, the role of diffusion weighted imaging (DWI) and apparent diffusion coefficient (ADC) have shown to be promising for T and N staging [11, 12](#)

Staging of Gastric Cancer

- Accurate staging of cancer is important for prognostication and directing further therapy. The most common staging system used for gastric malignancy is the American Joint Committee on Cancer tumour-node-metastases (AJCC TNM) score [1, 2](#)
- The arbitrary 10cm segment encompassing the distal 5cm of the oesophagus and proximal 5cm of the stomach (cardia), with the gastro-oesophageal junction GOJ in the middle, is an area of contention. Tumours arising ? 5cm from GOJ and within the proximal 5cm after crossing GOJ are staged as OC. All others are staged as GC [1](#)
- Current GC staging systems do not consider the anatomic extent of metastatic lymph nodes (mLNs) as a prognostic factor. However a recent report identified that the anatomic extent of mLNs significantly affects patient prognosis. [3](#) Incidences of nodal metastases is reported at 3 and 20% for stages T1a and T1b respectively

Primary tumour (T) stages

T0	No evidence of primary tumour
Tis	High grade dysplasia
T1a	Tumour invades lamina propria or muscularis mucosa
T1b	Tumor invades submucosa
T2	Tumour invades muscularis propria
T3	Tumour penetrates subserosal without invasion of visceral peritoneum or adjacent structures. Also include those extending into the gastrocolic or gastrohepatic ligaments, or into the greater or lesser omentum, without perforation of the visceral

peritoneum covering these structures
 T4a Tumour invades serosa (visceral peritoneum)
 T4b Tumour invades adjacent structures (e.g. spleen, transverse colon, liver, diaphragm, pancreas, abdominal wall, adrenal gland, kidney, small intestine, and retroperitoneum)

Regional lymph node (N) stages

N0 No regional lymph node metastasis
 N1 1-2 positive regional lymph nodes
 N2 3-6 positive regional lymph nodes
 N3 ≥7 positive regional lymph nodes

Metastases (M) stages

M0 No distant metastases
 M1 Distant metastases
 Positive peritoneal cytology

Stage	Tumour	Nodes	Metastases
IA	1	0	0
IB	2	0	0
	1	1	0
IIA	3	0	0
	2	1	0
	1	2	0
IIB	4a	0	0
	3	1	0
	2	2	0
	1	3	0
IIIA	4a	1	0
	3	2	0
	2	3	0
IIIB	4b	0	0
	4b	1	0
	4a	2	0
	3	3	0
IIIC	4b	2	0
	4b	3	0
	4a	3	0
IV	Any	Any	1

Computed Tomography (CT) Chest, Abdomen and Pelvis

- CT scan is widely employed for pre-treatment staging of gastric carcinoma. It is useful for examining local tumour extension, regional lymph node involvement, and the presence of distant metastasis [4, 5](#)

- A positive CT finding enables stratifying patients with unresectable disease due to locally advanced tumour and / or with distant metastasis

Positron Emission Tomography–Computed Tomography (PET-CT)

- A PET-CT can further rule out metastatic disease and used to solve clinical uncertainties or as a problem solving tool. However it is uncertain whether a PET-CT scan should be routinely performed for preoperative assessment [4](#)
- The use of 18F-FDG PET in gastric cancer assessment of [6](#)
 - Depth of tumour (T) - not useful
 - Lymph nodes (N) metastases - useful
 - Distant metastases (M) - low sensitivity but high specificity
 - Peritoneal metastases (M) - useful and high specificity
 - Recurrent disease - may be useful, but controversial
 - Treatment response - may be useful
 - Screening - not useful

Endoscopic Ultrasound (EUS)

- EUS is opted for selected patients where endoscopic therapy is considered. Staging laparoscopy and peritoneal cytology is indicated in stage T3-4 patients when the risk of peritoneal carcinomatosis and surgery is considered [5](#)
- Diagnostic accuracy of EUS might be considered clinically useful to guide physicians in the loco-regional staging of people with gastric carcinoma. However EUS performance is lower in diagnosing superficial tumours (T1a versus T1b) and lymph node status (positive versus negative) [7](#)

Diagnostic Laparoscopy

- When staging for advanced disease (?T3, N-any) where metastases is not detected, the role of staging laparoscopy and peritoneal cytology becomes vital especially when peritoneal metastasis is often undetected on CT [8, 9](#)
- Positive cytology as the only evidence for metastatic disease was present in up to 10% of patients with locally advanced gastric carcinoma. This potentially leads to a change in treatment strategies [8, 9](#)
- Concurrently, identified cytology negative patients can benefit from preoperative neoadjuvant chemotherapy
- Unfortunately this modality is still underutilized in the management of gastric carcinoma patients

Neoadjuvant Chemotherapy

- The MAGIC trial concluded that peri-operative chemotherapy with a regimen of epirubicin, cisplatin, and infused fluorouracil (ECF) improves overall and progression-free survival among patients with resectable adenocarcinoma of the stomach, lower oesophagus, or gastroesophageal junction, as compared with surgery alone. The trial also demonstrated a survival benefit, in the five-year survival rate and the reduction in the risk of death in the chemotherapy group [10](#)

References

Date of literature search: March 2015

The search methodology is available on request. [Email](#)

References are graded from Level I to V according to the Oxford Centre for Evidence-Based Medicine, Levels of Evidence. [Download the document](#)

1. Edge S, Byrd D, Compton C, Fritz A, Greene F, Trotti A. **AJCC Cancer staging manual**. 7th ed. New York: Springer-Verlag; 2010. (Guideline)
2. Compton C, Byrd D, Garcia-Aguilar J, Kurtzman S, Olawaiye A, Washington M. **Stomach**. AJCC Cancer Staging Atlas. 2nd ed. New York: Springer-Verlag; 2012. (Guideline)
3. Son T, Hyung WJ, Kim JW, Kim HI, An JY, Cheong JH, et al. **Anatomic extent of metastatic lymph nodes: still important for gastric cancer prognosis**. *Ann Surg Oncol*. 2014;21(3):899-907. (Level III evidence). [View the reference](#)
4. Dixon M, Cardoso R, Timmouth J, Helyer L, Law C, Swallow C, et al. **What studies are appropriate and necessary for staging gastric adenocarcinoma? Results of an international RAND/UCLA expert panel**. *Gastric Cancer* 2014;17(2):377-82. (Level III/IV evidence). [View the reference](#)
5. De Manzoni G, Baiocchi GL, Framarini M, De Giuli M, D'Ugo D, Marchet A, et al. **The SIC-GIRCG 2013 Consensus Conference on Gastric Cancer**. *Updates Surg*. 2014;66(1):1-6. (Level III/IV evidence). [View the reference](#)
6. Shimada H, Okazumi S, Koyama M, Murakami K. **Japanese Gastric Cancer Association Task Force for Research Promotion: clinical utility of 18F-fluoro-2-deoxyglucose positron emission tomography in gastric cancer. A systematic review of the literature**. *Gastric Cancer*. 2011;14(1):13-21. (Level II evidence). [View the reference](#)
7. Mocellin S, Pasquali S. **Diagnostic accuracy of endoscopic ultrasonography (EUS) for the preoperative locoregional staging of primary gastric cancer**. *Cochrane Database Syst Rev*. 2015;2:CD009944. (Level II evidence). [View the reference](#)
8. De Andrade JP, Mezhir JJ. **The critical role of peritoneal cytology in the staging of gastric cancer: an evidence-based review**. *J Surg Oncol*. 2014;110(3):291-7. (Review article). [View the reference](#)
9. Tourani SS, Cabalag C, Link E, Chan ST, Duong CP. **Laparoscopy and peritoneal cytology: important prognostic tools to guide treatment selection in gastric adenocarcinoma**. *ANZ J Surg*. 2015;85(1-2):69-73. (Level III evidence). [View the reference](#)
10. Cunningham D, Allum WH, Stenning SP, Thompson JN, Van de Velde CJ, Nicolson M, et al. **Perioperative chemotherapy versus surgery alone for resectable gastroesophageal cancer**. *N Engl J Med*. 2006;355(1):11-20. (Level I evidence). [View the reference](#)
11. Caivano R, Rabasco P, Lotumolo A, F DA, Zandolino A, Villonio A, et al. **Gastric cancer: The role of diffusion weighted imaging in the preoperative staging**. *Cancer Invest*. 2014;32(5):184-90. (Level III evidence). [View the reference](#)
12. Liu S, Guan W, Wang H, Pan L, Zhou Z, Yu H, et al. **Apparent diffusion coefficient value of gastric cancer by diffusion-weighted imaging: correlations with the histological differentiation and Lauren classification**. *Eur J Radiol*. 2014;83(12):2122-8. (Level III evidence). [View the reference](#)

Information for Consumers



Information from this website	Information from the Royal Australian and New Zealand College of Radiologists' website
<p>Radiation Risks of X-rays and Scans</p> <p>Computed Tomography (CT)</p> <p>Positron Emission Tomography (PET)</p> <p>Ultrasound</p>	<p>Computed Tomography (CT)</p> <p>Iodine-Containing Contrast Medium</p> <p>Radiation Risk of Medical Imaging During Pregnancy</p> <p>Radiation Risk of Medical Imaging for Adults and Children</p> <p>Ultrasound</p> <p>Nuclear Medicine</p> <p>PET Scan</p>

Copyright


© Copyright 2015, Department of Health Western Australia. All Rights Reserved. This web site and its content has been prepared by The Department of Health, Western Australia. The information contained on this web site is protected by copyright.

Legal Notice

Please remember that this leaflet is intended as general information only. It is not definitive and The Department of Health, Western Australia can not accept any legal liability arising from its use. The information is kept as up to date and accurate as possible, but please be warned that it is always subject to change.

File Formats

Some documents for download on this website are in a Portable Document Format (PDF). To read these files you might need to download Adobe Acrobat Reader.





[Legal Matters](#)