

Diagnostic Imaging Pathways - Breast Cancer (Staging)

Population Covered By The Guidance

This pathway provides guidance for the staging of patients with histologically proven breast carcinoma, and its effect on management.

Date reviewed: January 2012

Date of next review: 2017/2018

Published: January 2012

Quick User Guide

Move the mouse cursor over the **PINK** text boxes inside the flow chart to bring up a pop up box with salient points.

Clicking on the **PINK** text box will bring up the full text.

The relative radiation level (RRL) of each imaging investigation is displayed in the pop up box.

SYMBOL	RRL	EFFECTIVE DOSE RANGE
	None	0
	Minimal	< 1 millisieverts
	Low	1-5 mSv
	Medium	5-10 mSv
	High	>10 mSv

Pathway Diagram

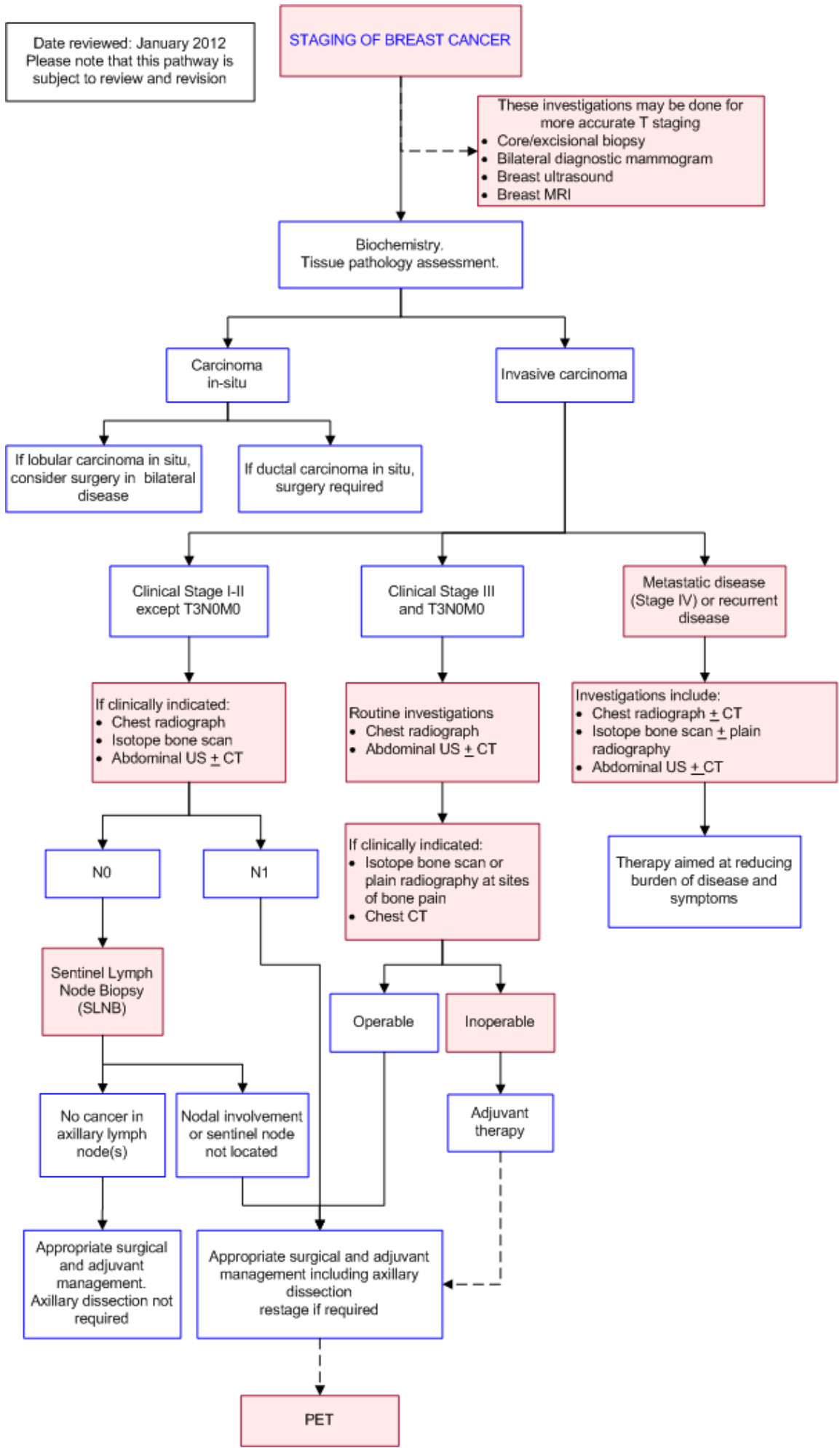


Image Gallery

Note: These images open in a new page

1 **Breast Carcinoma**

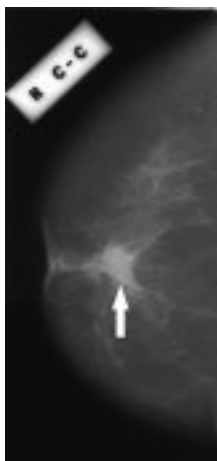

Image 1 (Breast Mammography): Stellate lesion with malignant calcification. In addition, there is inversion of the nipple and adjacent skin thickening. The features are highly suspicious for a breast carcinoma.

2a **Breast Carcinoma**

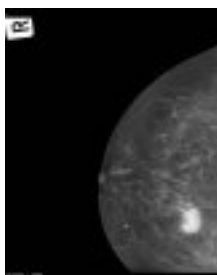

Image 2a (Mammogram, right breast): A non-calcified 22mm mass is present in the upper inner quadrant of the right breast.

2b **Breast Carcinoma**

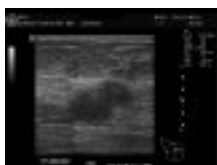

Image 2b (Ultrasound, right breast): Ultrasound of the same lesion showed an ill-defined solid mass with irregular margins, distortion of adjacent stroma and posterior acoustic shadowing, features which are suspicious for malignancy. Biopsy confirmed an invasive ductal carcinoma.

3a **Breast Carcinoma with Nodal Involvement**

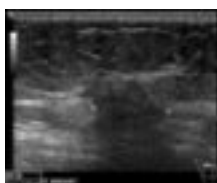
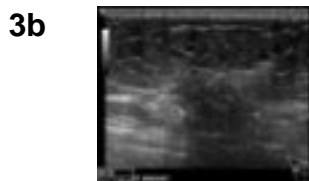


Image 3a and 3b (Breast Ultrasound): An irregular, hypoechoic area of parenchyma measuring 20mm in diameter is located in the upper outer quadrant/axillary tail region of the right breast. The features are suspicious for a breast carcinoma.



3c **Breast Carcinoma with Nodal Involvement**




Image 3c (Sentinel Lymph Node Scintigraphy): Imaging from the same patient using antimony colloid (^{99m}Tc Sb Colloid) administered under imaging guidance in a peritumoural and intradermal location in relation to the right upper, outer quadrant breast carcinoma. Imaging was performed for 2.5 hours. Towards the end of this imaging period, there was faint uptake of

activity high in the right axilla, likely representing nodal activity and this was marked on the skin.

4a



Breast Carcinoma

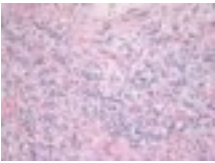
Image 4a: Mastectomy showing an irregular pale tumour (arrow) with surrounding fibrosis consistent with a breast carcinoma.

4b

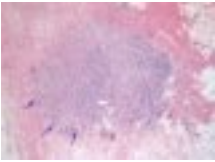

Image 4b (H&E, x2.5): Histological section of a moderately differentiated (Grade 2) invasive ductal carcinoma, type not otherwise specified, infiltrating through the breast parenchyma and surrounded by desmoplastic stroma. Occasional poorly formed tubules can be seen at the periphery (arrows).

5



Breast Carcinoma

Image 5 (H&E, x10): Histological section of a typical invasive lobular carcinoma showing the classical alignment of single cells in rows.

6



Metastatic Breast Carcinoma

Image 6 (H&E, x2.5): Histological section of a lymph node with metastatic breast carcinoma. The pale areas represent extensive replacement of the nodal parenchyma with solid sheets of malignant cells. Few residual follicles with germinal centres are present (arrows).

Teaching Points

- Accurate staging is essential for therapeutic decision making and prognostic information
- Imaging modalities that can be utilised in the 'Tumour' stage of disease include
 - Biopsy
 - Mammogram
 - Ultrasound
 - MRI
- The extent of imaging required for the detection of metastatic disease is dependant on locoregional staging and may include
 - Chest radiograph
 - CT chest
 - Ultrasound +/- CT of the abdomen
 - Bone scan
 - PET scan

Abdominal Imaging in Breast Cancer: Ultrasound and Computed Tomography (CT)

- The liver is the third most common site for breast cancer metastasis
- Abdominal imaging as part of routine staging investigations is recommended in patients with Stage III or greater disease. Imaging usually consists of a combination of ultrasound and computed tomography [17,18](#)

- The sensitivity and specificity for diagnosing breast cancer metastasis to liver using ultrasound was 30% and 99% respectively [19](#)
- Detection rates for hepatic metastasis from breast cancer in Stage I, II, and III disease were 0%, 0.4%, and 2%-5.4% respectively [18,25](#)
- CT with the administration of contrast is used to characterise liver lesions. Images are commonly taken during the
 - Arterial phase (20-30 seconds after administration of contrast): useful for identifying hypervascular lesions
 - Portal venous phase (70-80 seconds after administration of contrast) - often sufficient for hypovascular metastases
- The CT appearance of breast cancer metastases are typically uniformly hypoattenuating or hypoattenuating with rim enhancement but this is non-specific [43](#)

Skeletal Imaging in Breast Cancer: Isotope Bone Scan and Plain Radiography

- Isotope bone scans are the imaging modality of choice in detecting bone metastases [22,23](#)
 - More sensitive than plain radiography for the detection of early bone metastases [24](#)
 - The incidence of bone metastases on bone scan in patients with Stage I, II and III disease is 0.5%-0.8%, 1.1-2.4%, and 8%-16% [18,25](#)
 - In a patient with foci of increased uptake and a known primary tumour, the scan strongly suggests metastases [22](#)
 - Advantages: allows total body survey [22,23](#)
 - Limitations: radiographic correlation may be required in some patients with positive bone scan because of non specificity of findings on radioisotope imaging [22,26](#)
- In certain malignancies particularly with lytic bone metastases FDG PET is more sensitive than bone scan [23,26](#)

Chest Radiograph +/- Computed Tomography (CT)

- The thorax is the second most common site for breast cancer metastases after bone
- According to published clinical guidelines all patients with Stage III and IV breast cancer should receive a staging chest radiograph. There is no consensus regarding the use of routine chest radiograph in stage I and II disease [3,17,18](#)
- For stage I and II breast cancer, detection rates range from 0%-0.1% to 0.2%-0.8% respectively. There is no evidence to support a routine chest radiograph in patients with clinical stage I or II disease [19,20,21](#)
- If a lesion is detected on plain radiography, computed tomography should be performed for further assessment, and as a baseline to monitor response to therapy [3,17](#)

Diagnostic Mammography

- Standard mammography involves two views: cranio-caudal and medio-lateral oblique [3](#)
- The diagnostic accuracy of mammography is enhanced through the use of magnification views (magnified, coned compression views), which visualise only a small area of breast tissue but gives better contrast resolution and spatial detail [3-8](#)
- Abnormalities on mammography are generally categorised as [3](#)



- Mass lesions
 - Asymmetric densities
 - Architectural disturbances
 - Calcifications
 - A combination of these
- Although it is an excellent tool for evaluating breast lesions, mammography does have an inherent false-negative rate [9](#)
 - Mammography is not as sensitive in detecting abnormal lesions in dense breast tissue and for this reason, ultrasound is preferred over mammography in women younger than 35 [3](#)
 - The radiation exposure and hence risk of malignancy secondary to mammography is believed to be extremely low [7](#)

Breast Magnetic Resonance Imaging (MRI)

- Specialised exam which requires the interpretation of an expert breast imaging team working with a multidisciplinary treatment team [17](#)
- Meta-analysis of 44 studies indicates an overall sensitivity of 90% and specificity of 72% for the detection of breast cancer [45](#)
- May be useful for further evaluation of indeterminate or suspicious breast lesions detected on mammography or ultrasound [10,11](#)
- May be used in breast cancer staging to define the extent of the primary tumour or to detect multifocal/multicentric disease in the ipsilateral breast. [17](#) MRI detects additional disease unidentified on mammogram and ultrasound in up to 16% of women [46](#)
- May also be used to screen for contralateral cancer at the time of initial diagnosis. [17](#) Evidence indicates that MRI of the contralateral breast in women with recently diagnosed breast cancer detects lesions missed by other modalities at the time of diagnosis in up to 3% of women [44](#)
- May have a role in determining the extent of disease and response to treatment for patients being considered for neoadjuvant therapy and breast conserving surgery. Conversion to more extensive surgery due to previously undiagnosed multifocal/multicentric disease occurs in up to 11% of patients [46](#) However there is no data that demonstrate the use of MRI in improving local recurrence or survival [47,48](#)
- May be useful in locating primary cancer in women with nodal metastases or Paget's disease of the nipple not previously identified on other modalities [15,17](#)
- Limitations [13,14](#)
 - False positive findings are common which means that surgical decisions should not be based on MRI findings alone. Additional tissue sampling is recommended for new abnormalities detected by breast MRI [17](#)

Positron Emission Tomography (PET)

- In patients with diagnosed breast cancer, PET can be used to identify local or distant metastasis
- For the diagnosis of malignant breast lesions, PET has a sensitivity and specificity of 75%-93 and 73%-95% respectively [10,36,37](#)
- Diagnostic accuracy is reduced with lobular carcinomas and small breast cancers less than 10mm in diameter
- More sensitive than combined ultrasound and mammography for diagnosing multifocal/multicentric breast cancer [37](#)
- For the detection of metastasis to axillary lymph nodes

- The sensitivity and specificity is 61%-94% and 80%-97% respectively [37-41](#)
- Limited ability to detect micrometastases, make it unsuitable for replacement of axillary lymph node sampling/excision [10](#)
- Advantages: non-invasive method of detecting lymph node involvement. High specificity for staging axilla [10](#)
- Able to provide comprehensive overview of involvement including that of IM nodes, skin involvement, and extent of tumour [27](#)
- For detection of bone metastases [26](#)
 - Sensitivity of 61%-100% and specificity 96%-100%
 - May be more sensitive than bone scan for detection of osteolytic bone metastasis, however it is limited by availability and cost
- Superior to conventional diagnostic imaging for detecting unsuspected metastatic breast cancer. FDG-PET detected remote metastases with a sensitivity of 86%, and specificity of 90% [42](#)
- Currently there is no Medicare rebate in Australia for the use of PET imaging in breast cancer. PET is therefore limited to re-staging and monitoring disease response to therapy

Sentinel Lymph Node Biopsy

- Based on the theory that sentinel lymph nodes are the first local nodes to drain lymph from the tumour and would be the node most likely to have neoplastic deposits in the event of lymphatic spread and indicate the status of the remaining nodal chain [27,28](#)
- Involves injection of technetium-99m labelled sulfur colloid particles and/or blue dye into tissue surround the tumour pre-operatively. Evidence suggests that using a combination of radioactive tracer and blue dye is more successful than any one technique alone [27](#)
- A handheld gamma camera is used intra-operatively to detect the sentinel lymph node(s). All nodes with significantly higher radioactivity and/or blue-staining are then excised and sent for histopathological analysis [27,29](#)
- Identification of lymph nodes most likely to contain metastatic disease allows a detailed analysis including use of serial sectioning, immunohistological staining, and reverse-transcriptase polymerase chain reaction. This contrasts with axillary lymph node dissection where random nodes from the lymph node chain are selected for microscopy [29,30](#)
- Increased detection rate of lymph node metastasis and detection of micrometastases results in more accurate staging compared to axillary lymph node dissection. The clinical benefits of detecting micrometastases however, has not been established [29](#)
- Compared with axillary lymph node dissection, the sensitivity, specificity, and negative predictive value for sentinel lymph node biopsy is 87%-93%, 100%, and 95%-96% respectively [31-35](#)
- Advantages compared with axillary lymph node dissection include [30,31](#)
 - Less invasive
 - Ability to identify sentinel lymph nodes outside of the axilla
 - Patients without metastatic nodal disease can avoid axillary lymph node dissection
- Disadvantages of sentinel lymph node biopsy include [30,31](#)
 - Technically challenging procedure with significant variation in success rates between surgeons
 - One study found significantly higher failure rate in patients with prior excisional biopsy
 - Likelihood of finding malignancy in non-sentinel nodes is higher in larger tumours (e.g. T3 vs T1 or T2) and therefore this procedure is not recommended in patients with large local tumours

Staging of Breast Cancer

- The American Joint Committee on Cancer Staging TMN method is the most widely used method of breast cancer staging [1,2](#)
- Accurate staging is essential for therapeutic decision making and prognostic information
- Axillary lymph node status is the most important prognostic indicator in breast cancer
- **TNM staging of breast cancer - American Joint Committee on Cancer [1,2](#)**
 - Primary tumour (T)
 - TX primary tumour cannot be assessed
 - T0 no evidence of primary tumour
 - Tis carcinoma in situ
 - T1 tumour < 2cm in greatest dimension
 - T2 tumour > 2cm but < 5cm in greatest dimension
 - T3 tumour > 5cm in greatest dimension
 - T4a tumour of any size with direct extension to chest wall not including pectoralis muscle
 - T4b tumour of any size with skin oedema (including peau d'orange) or ulceration of the skin of the breast, or satellite skin nodules confined to the ipsilateral breast
 - T4c both T4a and 4b
 - T4d inflammatory carcinoma
 - Regional lymph nodes (N)
 - NX regional lymph nodes cannot be assessed (e.g. previously removed)
 - N0 no regional lymph node metastasis
 - N1 metastasis in movable ipsilateral axillary lymph node(s)
 - N2 metastases in ipsilateral axillary lymph node fixed or matted; or in clinically apparent internal mammary lymph nodes in the absence of clinically apparent axillary lymph node metastasis
 - N3 metastasis in ipsilateral infraclavicular lymph node(s), or in clinically apparent ipsilateral internal mammary lymph node(s) and in the presence of clinically evident axillary lymph node metastasis; or metastasis in ipsilateral supraclavicular lymph node(s) with or without axillary or internal mammary lymph node involvement
 - Regional lymph nodes (pN) - based on axillary lymph node dissection +/- sentinel lymph node dissection
 - pNX regional lymph nodes cannot be assessed
 - pN0 no regional lymph node metastasis histologically, no additional examination for isolated tumour cells
 - pN1 metastasis in 1 to 3 axillary and/or internal mammary lymph nodes with microscopic disease detected by sentinel lymph node dissection but not clinically apparent
 - PN2 metastasis in 4 to 9 axillary lymph nodes, or in clinically apparent internal mammary lymph nodes in the absence of axillary lymph node metastasis
 - PN3 metastasis in > 10 axillary lymph nodes, or in infraclavicular lymph nodes; or in clinically apparent ipsilateral internal mammary lymph nodes in the presence of one or more positive axillary lymph nodes; or in > 3 axillary lymph nodes with clinically negative microscopic metastasis in internal mammary lymph nodes; or in ipsilateral supraclavicular lymph nodes
 - Distant metastasis (M)
 - MX distant metastasis cannot be assessed
 - M0 no distant metastasis
 - M1 distant metastasis



STAGE GROUPING	T	N	M
O	Tis		M0
		N0	
I	T1	N0	
			M0
IIA	T0	N1	
			M0
	T1	N1	M0
	T2	N0	M0
IIB	T2	N1	M0
	T3	N0	M0
IIIA	T0	N2	M0
	T1	N2	M0
	T2	N2	M0
	T3	N1	M0
	T3	N2	M0
IIIB	T4	N0	M0
	T4	N1	M0
	T4	N2	M0
IIIC	Any T	N3	M0
IV	Any T	Any N	M1

Breast Ultrasound

- Is an important diagnostic tool in the evaluation of breast lesions
- Often used complementary to mammography but may be the initial and only imaging modality required for women younger than 35 [3](#)
- Is the preferred initial imaging modality in pregnant and lactating women [4](#)
- Situations where ultrasound is useful include [3](#)
 - For evaluating palpable masses not seen on mammography
 - For further evaluation of indeterminate lesions seen on mammography
 - For detection of any underlying mass or altered architecture associated with calcification or asymmetric densities seen on mammography
 - For implant evaluation
 - For guidance of percutaneous biopsy

References

References are graded from Level I to V according to the Oxford Centre for Evidence-Based Medicine, Levels of Evidence. [Download the document](#)

1. Singletary SE, Allred C, Ashley P, et al. **Revision of the American Joint Committee on Cancer staging system for breast cancer.** J Clin Oncology. 2002;20:3628-36. (Guideline statement)
2. Greene F, Page D, Fleming I, et al. **AJCC cancer staging manual.** New York: Springer-Verlag; 2002
3. **Breast imaging: a guide for practice.** National Breast Cancer Centre, 2002. (Review article)
4. NHMRC National Breast Cancer Centre. **The investigation of a new breast symptom: a guide for general practitioners.** Woolloomooloo (NSW): NHMRC National Breast Cancer Centre, 1997. (Evidence based guideline)
5. Echlund GW. **The art of mammographic positioning, in radiological diagnosis of breast diseases.** Berlin: Springer, 1997.
6. Faulk RM, Sickles EA. **Efficacy of spot compression-magnification and tangential views in mammographic evaluation of palpable breast masses.** Radiology. 1992;185:87-90. (Level III evidence)
7. Feig SA. **The importance of supplementary mammographic views to diagnostic accuracy.** AJR Am J Roentgenol. 1988;151:40-1. (Review article)
8. Berkowitz JE, Gatewood OM, Gayler BW. **Equivocal mammographic findings: evaluation with spot compression.** Radiology. 1989;171:369-71. (Level IV evidence)
9. Foxcroft LM, Evans EB, Joshua HK, Hirst C. **Breast cancers invisible on mammography.** Aust NZ J Surg. 2000;70:162-7. (Level III evidence)
10. Heinisch M, Gallowitsch HJ, Mikosch P, et al. **Comparison of FDG-PET and dynamic contrast-enhanced MRI in the evaluation of suggestive breast lesions.** Breast. 2003;12:17-22. (Level III evidence)
11. Walter C, Scheidhauer K, Scharl A, et al. **Clinical and diagnostic value of preoperative MR mammography and FDG-PET in suspicious breast lesions.** Eur Radiol. 2003;13:1651-6. (Level III evidence)
12. Malich A, Boehm T, Facius M, et al. **Differentiation of mammographically suspicious lesions: evaluation of breast ultrasound, MRI, mammography and electrical impedance scanning as adjunctive technologies in breast cancer detection.** Clin Radiol. 2001;56:278-83. (Level II evidence). [View the reference](#)
13. Hata T, Takahashi H, Watanabe K, et al. **Magnetic resonance imaging for preoperative evaluation of breast cancer: a comparative study with mammography and ultrasonography.** J Am Coll Surg. 2004;198:190-7. (Level II/III evidence)
14. Fischer U, Kopka L, Grabbe E. **Breast carcinoma: effect of preoperative contrast-enhanced MR imaging on the therapeutic approach.** Radiology. 1999;213:881-8. (Level I evidence). [View the reference](#)
15. Harms SE, Rabinovitch R, Julian T, Rafferty E, Masood S, Weatehrall P. **Report of the working groups on breast MRI: report of the breast cancer staging group.** Breast J. 2004;10(S5):S3-8. (Discussion statement)
16. Wedegartner U, Bick U, Wortler K, Rummeny E, Bongartz G. **Differentiation between benign and malignant findings on MR-mammography: usefulness of morphological criteria.** Eur Radiol. 2001;11:1645-50. (Level II evidence). [View the reference](#)
17. NCCN Breast Cancer Panel. **Breast cancer: clinical practice guidelines in Oncology v1.2009.** National Comprehensive Cancer Network 2009.(Evidence based guideline). [View the reference](#)
18. Myers RE, Johnston M, Pritchard K, et al. **Baseline staging tests in primary breast cancer: a practice guideline.** CMAJ. 2001;164:1439-44. (Clinical guideline)
19. Ciatto S, Pacini P, Azzini V, et al. **Preoperative staging of primary breast cancer: a multicentric study.** Cancer. 1988;61:1038-40. (Level III/IV evidence)
20. Glynne-Jones R, Young T, Ahmed A, Ell PJ, Berry RJ. **How far investigations for occult metastases in breast cancer aid the clinician.** Clin Oncol (R Coll Radiol). 1991;3:65-72. (Level IV evidence)
21. Ravaioli A, Tassinari D, Pasini G, et al. **Staging of breast cancer: what standards should be**

- used in research and clinical practice?** Ann Oncol. 1998;9:1173-7. (Level III evidence)
22. Rybak LD, Rosenthal DI. **Radiological imaging for the diagnosis of bone metastases.** Q J Nucl Med. 2001;45:53-64. (Review article)
 23. Schaffer DL, Pendergrass HP. **Comparison of enzyme, clinical, radiographic and radiographic methods of detecting bone metastases from carcinoma of the prostate.** Radiology. 1976;121:431-4. (Level III evidence)
 24. Brar HS, Sisley JF, Johnson RH Jr. **Value of preoperative bone and liver scans and alkaline phosphatase in the evaluation of breast cancer patients.** Am J Surg. 1993;165:221-4. (Level III evidence)
 25. Cox MR, Gilliland R, Odling-Smee GW, Spence RAJ. **An evaluation of radionuclide bone scanning and liver ultrasonography for staging breast cancer.** Aust N Z J Surg. 1992;62:550-5. (Level II/III evidence)
 26. Hamaoka T, Madewell JE, Podoloff DA, Hortobagyi GN, Ueno NT. **Bone imaging in metastatic breast cancer.** J Clin Oncol. 2004;22:2942-53. (Review article)
 27. Aarsvold JN, Alazraki NP. **Update on detection of sentinel lymph nodes in patients with breast cancer.** Semin Nucl Med. 2005;35:116-28. (Review article)
 28. Kaleya RN, Heckman JT, Most M, Zager JS. **Lymphatic mapping and sentinel node biopsy: a surgical perspective.** Semin Nucl Med. 2005;35:129-34. (Review article)
 29. Albertini JJ, Lyman GH, Cox C, et al. **Lymphatic mapping and sentinel node biopsy in the patient with breast cancer.** JAMA. 1996;276:1818-22. (Level II evidence)
 30. Liberman L, Cody HS 3rd, Hill AD, et al. **Sentinel lymph node biopsy after percutaneous diagnosis of non-palpable breast cancer.** Radiology. 1999;211:835-44. (Level III evidence)
 31. Krag D, Weaver D, Ashikaga T, et al. **The sentinel node in breast cancer: a multicenter validation study.** N Engl J Med. 1998;339:941-6. (Level I evidence). [View the reference](#)
 32. Rubio IS, Korouian S, Cowan C, Krag DN, Colvert M, Klimberg VS. **Sentinel lymph node biopsy for staging breast cancer.** Am J Surg. 1998;176:532-7. (Level III evidence)
 33. Veronesi U, Galimberti V, Zurrada S, et al. **Sentinel lymph node biopsy as an indicator for axillary dissection in early breast cancer.** Eur J Cancer. 2001;37:454-8. (Level II evidence). [View the reference](#)
 34. O'Hea BJ, Hill AD, El-Shirbiny AM, et al. **Sentinel lymph node biopsy in breast cancer: initial experience at Memorial Sloan-Kettering Cancer Center.** J Am Coll Surg. 1998;186:423-7. (Level II evidence). [View the reference](#)
 35. Kuehn T, Vogl FD, Helms G. **Sentinel-node biopsy for axillary staging in breast cancer: results from a large prospective German multi-institutional trial.** Eur J Surg Oncol. 2004;30:252-9. (Level II evidence). [View the reference](#)
 36. Avril N, Rose CA, Schelling M, et al. **Breast imaging with positron emission tomography and fluorine-18 fluorodeoxyglucose: use and limitations.** J Clin Oncol. 2000;18:3495-502. (Level II evidence). [View the reference](#)
 37. Schirrmester H, Kuhn T, Guhlmann A, et al. **Fluorine-18 2-deoxy-2-fluoro-d-glucose PET in the preoperative staging of breast cancer: comparison with the standard staging procedures.** Eur J Nucl Med. 2001;28:351-8. (Level III evidence)
 38. Greco M, Crippa F, Agresti R, et al. **Axillary lymph node staging in breast cancer by 2-fluoro-2-deoxy-d-glucose positron emission tomography: clinical evaluation and alternative management.** J Natl Cancer Inst. 2001;93:630-5. (Level II evidence). [View the reference](#)
 39. Wahl RL, Siegel BA, Coleman E, Gatsonis C. **Prospective multicenter study of axillary nodal staging by positron emission tomography in breast cancer: a report of the staging of breast cancer with PET study group.** J Clin Oncol. 2004;22:277-85. (Level I evidence). [View the reference](#)
 40. Smith IC, Ogston KN, Whitford P, et al. **Staging of the axilla in breast cancer: accurate in vivo assessment using positron emission tomography with 2-(fluorine-18)-fluoro-2-deoxy-D-**



- glucose.** Ann Surg. 1998;228:20-7. (Level III evidence)
41. Avril N, Dose J, Janicke F, et al. **Assessment of axillary lymph node involvement in breast cancer patients with positron emission tomography using radiolabeled 2-(fluorine-18)-fluoro-2-deoxy-d-glucose.** J Natl Cancer Inst. 1996;88:1204-9. (Level II evidence). [View the reference](#)
 42. Dose J, Bleckmann C, Bachmann S, et al. **Comparison of fluorodeoxyglucose positron emission tomography and "conventional diagnostic procedures" for the detection of distant metastases in breast cancer.** Nucl Med Commun. 2002;23:857-64. (Level III evidence)
 43. Dubrow RA, David CL, Libshitz HI, Lorigan JG. **Detection of hepatic metastases in breast cancer: the role of nonenhanced and enhanced CT scanning.** J Comput Assist Tomogr. 1990;14(3):366-9. (Level IV evidence)
 44. Lehman C, Gatsonis C, Kuhl C, et al. **MRI evaluation of the contralateral breast in women with recently diagnosed breast cancer.** N Engl J Med. 2007;356:1295-303. (Level II evidence). [View the reference](#)
 45. Peters NH, Borel Rinkes IH, Zuithoff NP, et al. **Meta-analysis of MR imaging in the diagnosis of breast lesions.** Radiology. 2008;246(1):116-24. (Level I evidence)
 46. Houssami N, Ciatto S, Macaskill P, et al. **Accuracy and surgical impact of magnetic resonance imaging in breast cancer staging: systematic review and meta-analysis in detection of multifocal and multicentric cancer.** J Clin Oncol. 2008;26(19):3248-58. (Level I evidence). [View the reference](#)
 47. Solin LJ, Orel SG, Hwang WT, et al. **Relationship of breast magnetic resonance imaging to outcome after breast-conservation treatment with radiation for women with early-stage invasive breast carcinoma or ductal carcinoma in situ.** J Clin Oncol. 2008;26(3):386-91. (Level II evidence)
 48. Fischer U, Zachariae O, Baum F, et al. **The influence of preoperative MRI of the breasts on recurrence rate in patients with breast cancer.** Eur Radiol. 2004;14(10):1725-31. (Level II evidence)

Information for Consumers

Information from this website	Information from the Royal Australian and New Zealand College of Radiologists' website
<p>Consent to Procedure or Treatment</p> <p>Radiation Risks of X-rays and Scans</p> <p style="padding-left: 40px;">Bone Scan</p> <p>Magnetic Resonance Imaging (MRI)</p> <p style="padding-left: 40px;">Ultrasound</p> <p style="padding-left: 40px;">Plain Radiography (X-ray)</p>	<p style="padding-left: 40px;">Computed Tomography (CT)</p> <p style="padding-left: 40px;">Contrast Medium (Gadolinium versus Iodine)</p> <p style="padding-left: 40px;">Gadolinium Contrast Medium</p> <p style="padding-left: 40px;">Iodine-Containing Contrast Medium</p> <p style="padding-left: 40px;">Magnetic Resonance Imaging (MRI)</p> <p style="padding-left: 40px;">Plain Radiography/X-rays</p>

[Radiation Risk of Medical Imaging During Pregnancy](#)

[Radiation Risk of Medical Imaging for Adults and Children](#)

[Ultrasound](#)

[Nuclear Medicine](#)

[Nuclear Medicine Bone Scan](#)

[Breast Core Biopsy](#)

[Breast Fine Needle Aspiration \(FNA\)](#)

[Breast Hookwire Localisation](#)

[Breast MRI](#)

[Breast Ultrasound](#)

[Vacuum-Assisted Core Biopsy](#)

Copyright

© Copyright 2015, Department of Health Western Australia. All Rights Reserved. This web site and its content has been prepared by The Department of Health, Western Australia. The information contained on this web site is protected by copyright.

Legal Notice

Please remember that this leaflet is intended as general information only. It is not definitive and The Department of Health, Western Australia can not accept any legal liability arising from its use. The information is kept as up to date and accurate as possible, but please be warned that it is always subject to change

File Formats

Some documents for download on this website are in a Portable Document Format (PDF). To read these files you might need to download Adobe Acrobat Reader.





[Legal Matters](#)