

# Diagnostic Imaging Pathways - Nipple Discharge

## Population Covered By The Guidance

This pathway provides guidance on the imaging of adult female patients with new onset of nipple discharge.

**Date reviewed: May 2018**

**Date of next review: May 2021**






**Published: November 2018**

## Quick User Guide

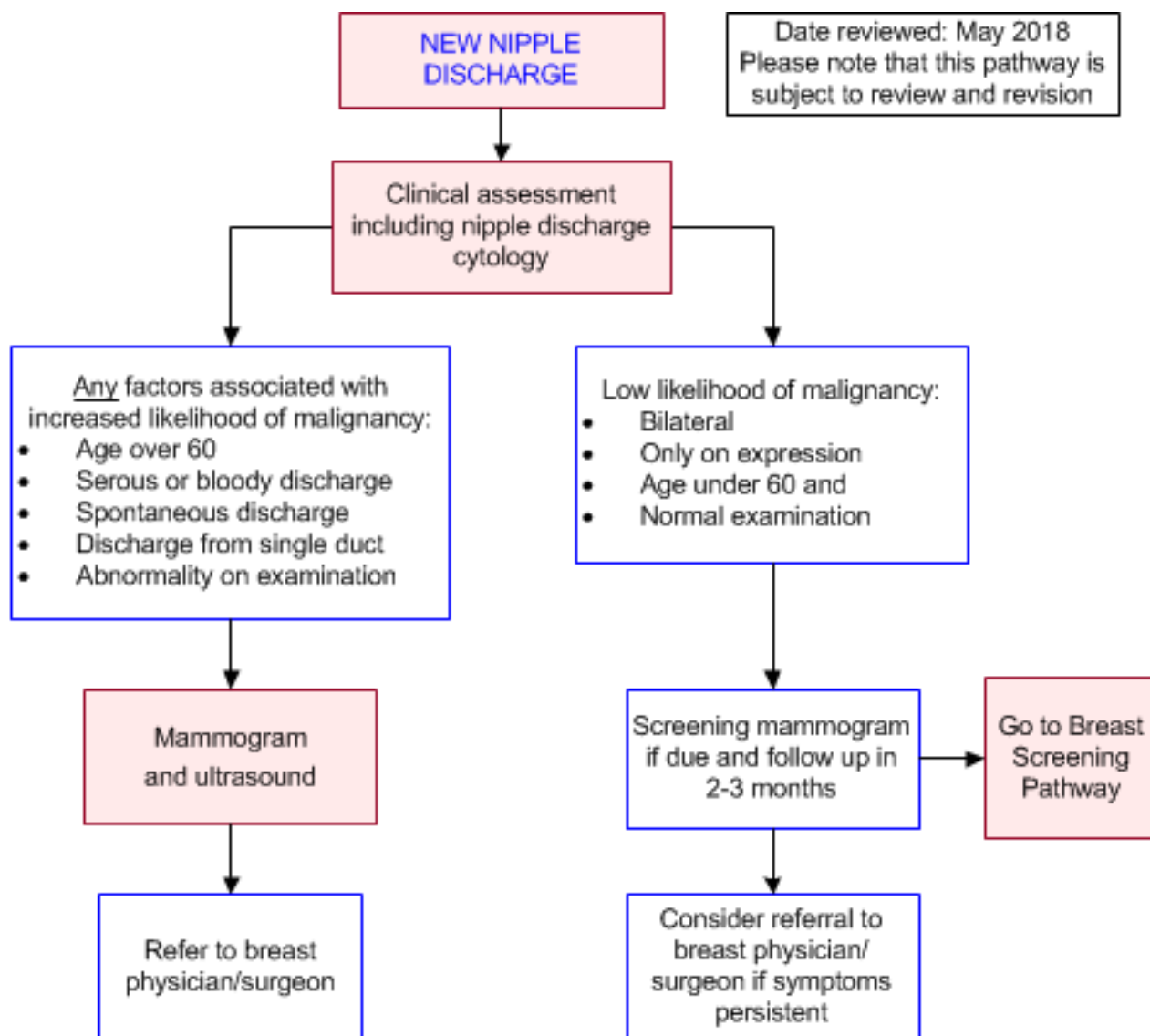
Move the mouse cursor over the **PINK** text boxes inside the flow chart to bring up a pop up box with salient points.

Clicking on the **PINK** text box will bring up the full text.

The relative radiation level (RRL) of each imaging investigation is displayed in the pop up box.

| SYMBOL   | RRL     | EFFECTIVE DOSE RANGE |
|--|---------|----------------------|
|  | None    | 0                    |
|  | Minimal | < 1 millisieverts    |
|  | Low     | 1-5 mSv              |
|  | Medium  | 5-10 mSv             |
|  | High    | >10 mSv              |

## Pathway Diagram

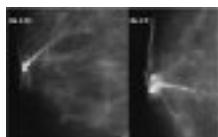


Breast MRI

## Image Gallery

*Note: These images open in a new page*

1



### Intraductal Papilloma

Image 1 (Ductography): Lateral-medial and craniocaudad magnified ductogram demonstrating the irregular filling defect (arrow) of intraductal

papilloma.

## Teaching Points

- 97% of nipple discharge is caused by benign disease [1](#) but it may be the presenting complaint for malignancy
- Nipple discharge can be classified as physiological or pathological
- Physiological discharge is usually bilateral, from multiple ducts, only on expression and can be milky, green, grey, yellow or black
  - Causes include pregnancy, endocrine disorders and medications [2](#)
  - The risk of cancer is extremely low in the absence of any pathological features [3, 4](#)
  - Imaging is not recommended in this situation [1, 5-7](#) and medical work up should be done including ?-hCG to rule out pregnancy [2](#)
- The features of pathological discharge include the following:
  - Age > 60 [8, 9](#)
  - Serous or bloody discharge [10, 11](#)
  - Spontaneous discharge [1, 11](#)
  - Discharge from single duct
  - Abnormality on examination [1](#)
- These features are associated with an increased risk of malignancy and further imaging is recommended when any of these features are present [6](#)
- Malignancy occurs in 5-25% of women with pathological discharge [10, 12, 13](#)
- The most common malignancy is ductal carcinoma in-situ (DCIS)
- The most common cause of pathological discharge is papilloma. [14, 15](#) Although benign, they may harbour malignancy. [16](#) All women with nipple discharge should be assessed with the Triple Test, including examination, imaging and tissue biopsy. [6](#) The Triple Test is positive when any component is indeterminate, suspicious or malignant
- Mammography and ultrasound do not detect all lesions presenting with nipple discharge [11, 17](#) and do not reliably differentiate between malignant and benign lesions [17, 18](#)
- Discharge cytology has a high false negative rate [19](#) so it is not useful to rule out malignancy
- Surgical referral is recommended if symptoms are persistent, despite normal investigations [6](#)
- MRI may be considered by a breast specialist in limited cases where mammography and ultrasound are negative and there is persisting clinical concern
- Surgical management may be required for a definitive tissue diagnosis or treatment of the underlying pathology

## References

Date of literature search: April 2018

References are graded from Level I to V according to the Oxford Centre for Evidence-Based Medicine, Levels of Evidence. [Download the document](#)

- [1.](#) Gulay H, Bora S, Kilicturgay S, Hamaloglu E, Goksel HA. **Management of nipple discharge.** J Am Coll Surg. 1994;178(5):471-4. (Level III evidence). [View the reference](#)
- [2.](#) Salzman B, Fleegle S, Tully AS. **Common breast problems.** Am Fam Physician.

- 2012;86(4):343-9. (Review article). [View the reference](#)
3. Bahl M, Baker JA, Greenup RA, Ghate SV. **Diagnostic value of ultrasound in female patients with nipple discharge.** AJR Am J Roentgenol. 2015. ;205(1):203-8. (Level III evidence). [View the reference](#)
  4. Goksel HA, Yagmurduur MC, Demirhan B, Isiklar I, Karakayali H, Bilgin N, et al. **Management strategies for patients with nipple discharge.** Langenbecks Arch Surg. 2005;390(1):52-8. (Level II-III evidence). [View the reference](#)
  5. Lee SJ, Trikha S, Moy L, Baron P, diFlorio RM, Green ED, et al. **ACR appropriateness criteria((R)) evaluation of nipple discharge.** J Am Coll Radiol. 2017;14(5s):S138-s53. (Guideline). [View the reference](#)
  6. **The investigation of a new breast symptom: a guide for general practitioners 2017.** Cancer Australia. 2017. (Review article). [View the reference](#)
  7. Gray RJ, Pockaj BA, Karstaedt PJ. **Navigating murky waters: a modern treatment algorithm for nipple discharge.** Am J Surg. 2007;194(6):850-4; discussion 4-5. (Level III evidence). [View the reference](#)
  8. Youk JH, Kim EK, Kwak JY, Son EJ, Park BW, Kim SI. **Benign papilloma without atypia diagnosed at US-guided 14-gauge core-needle biopsy: clinical and US features predictive of upgrade to malignancy.** Radiology. 2011;258(1):81-8. (Level II-III evidence). [View the reference](#)
  9. Seltzer MH, Perloff LJ, Kelley RI, Fitts WT, Jr. **The significance of age in patients with nipple discharge.** Surg Gynecol Obstet. 1970;131(3):519-22. (Level II evidence). [View the reference](#)
  10. Chen L, Zhou WB, Zhao Y, Liu XA, Ding Q, Zha XM, et al. **Bloody nipple discharge is a predictor of breast cancer risk: a meta-analysis.** Breast Cancer Res Treat. 2012;132(1):9-14. (Level I evidence). [View the reference](#)
  11. Morrogh M, Park A, Elkin EB, King TA. **Lessons learned from 416 cases of nipple discharge of the breast.** Am J Surg. 2010;200(1):73-80. (Level II-III evidence). [View the reference](#)
  12. Murad TM, Contesso G, Mouriessse H. **Nipple discharge from the breast.** Ann Surg. 1982;195(3):259-64. (Level II evidence). [View the reference](#)
  13. King TA, Carter KM, Bolton JS, Fuhrman GM. **A simple approach to nipple discharge.** Am Surg. 2000;66(10):960-5; discussion 5-6. (Level III evidence). [View the reference](#)
  14. Orel SG, Dougherty CS, Reynolds C, Czerniecki BJ, Siegelman ES, Schnall MD. **MR imaging in patients with nipple discharge: initial experience.** Radiology. 2000;216(1):248-54. (Level II-III evidence). [View the reference](#)
  15. Gioffre Florio M, Manganaro T, Pollicino A, Scarfo P, Micali B. **Surgical approach to nipple discharge: a ten-year experience.** J Surg Oncol. 1999;71(4):235-8. (Level III evidence). [View the reference](#)
  16. Glenn ME, Throckmorton AD, Thomison JB, 3rd, Bienkowski RS. **Papillomas of the breast 15 mm or smaller: 4-year experience in a community-based dedicated breast imaging clinic.** Ann Surg Oncol. 2015;22(4):1133-9. (Level III evidence). [View the reference](#)
  17. Cabioglu N, Hunt KK, Singletary SE, Stephens TW, Marcy S, Meric F, et al. **Surgical decision making and factors determining a diagnosis of breast carcinoma in women presenting with nipple discharge.** J Am Coll Surg. 2003;196(3):354-64. (Level III evidence). [View the reference](#)
  18. Simmons R, Adamovich T, Brennan M, Christos P, Schultz M, Eisen C, et al. **Nonsurgical evaluation of pathologic nipple discharge.** Ann Surg Oncol. 2003;10(2):113-6. (Level II-III evidence). [View the reference](#)
  19. Das DK, Al-Ayadhy B, Ajrawi MT, Shaheen AA, Sheikh ZA, Malik M, et al. **Cytodiagnosis of nipple discharge: a study of 602 samples from 484 cases.** Diagn Cytopathol. 2001;25(1):25-37. (Level II-III evidence). [View the reference](#)
  20. Ashfaq A, Senior D, Pockaj BA, Wasif N, Pizzitola VJ, Giurescu ME, et al. **Validation study of a modern treatment algorithm for nipple discharge.** Am J Surg. 2014;208(2):222-7. (Level III evidence). [View the reference](#)
  21. Lorenzon M, Zuiani C, Linda A, Londero V, Girometti R, Bazzocchi M. **Magnetic resonance**



**imaging in patients with nipple discharge: should we recommend it?** Eur Radiol. 2011;21(5):899-907. (Level III evidence). [View the reference](#)

22. Cardenosa G, Eklund GW. **Benign papillary neoplasms of the breast: mammographic findings.** Radiology. 1991;181(3):751-5. (Level III evidence). [View the reference](#)
23. Rissanen T, Reinikainen H, Apaja-Sarkkinen M. **Breast sonography in localizing the cause of nipple discharge: comparison with galactography in 52 patients.** J Ultrasound Med. 2007;26(8):1031-9. (Level III evidence). [View the reference](#)
24. Morrogh M, Morris EA, Liberman L, Borgen PI, King TA. **The predictive value of ductography and magnetic resonance imaging in the management of nipple discharge.** Ann Surg Oncol. 2007;14(12):3369-77. (Level III evidence). [View the reference](#)
25. Sanders LM, Daigle M. **The rightful role of MRI after negative conventional imaging in the management of bloody nipple discharge.** Breast J. 2016;22(2):209-12. (Level III evidence). [View the reference](#)
26. Bahl M, Gadd MA, Lehman CD. **Journal club: diagnostic utility of MRI after negative or inconclusive mammography for the evaluation of pathologic nipple discharge.** AJR Am J Roentgenol. 2017;209(6):1404-10. (Level III evidence). [View the reference](#)

## Information for Consumers

| Information from this website  | Information from the Royal Australian and New Zealand College of Radiologists' website     |
|--|--|
| <p><a href="#">Consent to Procedure or Treatment</a></p> <p><a href="#">Radiation Risks of X-rays and Scans</a></p> <p><a href="#">Plain Radiography (X-ray)</a></p> | <p><a href="#">Diagnostic Mammography</a></p> <p><a href="#">Screening Mammography</a></p> |

## Mammography

- Recommend as the initial investigation of pathological nipple discharge in conjunction with ultrasound [6](#)
- Although mammography is an excellent tool for evaluating breast lesions, the sensitivity is lower for women presenting with nipple discharge (20) as the associated lesions are often small, intraductal, retroareolar and non-calcified [3](#), [21-22](#) and hence, not readily demonstrated on mammography
- Mammography is useful for demonstrating microcalcifications associated with DCIS
- Where a lesion is identified on imaging, the radiologist may proceed to fine needle aspiration (FNA) or core biopsy

## Ultrasound

- Recommended as the initial investigation of pathological nipple discharge in conjunction with mammography
- Detects lesions not visible on mammography in 63-69% of pathological discharge [11](#), [23](#)
- Where a lesion is identified on imaging, the radiologist may proceed to fine needle aspiration (FNA) or core biopsy
- The diagnostic accuracy of ultrasound is dependent on the expertise of the sonographer as well as the reporting radiologist

## Breast MRI

- Breast MRI may be considered by a breast specialist in limited cases where the mammography and ultrasound are negative and there is persisting clinical concern
- Breast MRI is performed with gadolinium contrast – renal impairment and contrast sensitivity are contraindications
- Lesions appear as mass or non-mass enhancement in ductal or segmental distribution [5](#)
- MRI also identifies index lesions in peripheral ducts, outside the area normally encompassed by ductography or targeted US. (24) Asymptomatic lesions in the contralateral breast may also be identified [25](#)
- MRI-guided biopsy can be performed if a lesion is identified
- Where MRI and mammogram are both negative, the risk of malignancy is low at 4% and surveillance rather than surgical excision may be suitable [26](#)

## Discharge Cytology

- Discharge cytology has a high false negative rate [19](#) so it is not useful to rule out malignancy but can provide useful information when cells indicative of malignancy are present

## Copyright

© Copyright 2015, Department of Health Western Australia. All Rights Reserved. This web site and its content has been prepared by The Department of Health, Western Australia. The information contained on this web site is protected by copyright.

## Legal Notice

Please remember that this leaflet is intended as general information only. It is not definitive and The Department of Health, Western Australia can not accept any legal liability arising from its use. The information is kept as up to date and accurate as possible, but please be warned that it is always subject to change

## File Formats

Some documents for download on this website are in a Portable Document Format (PDF). To read these files you might need to download Adobe Acrobat Reader.



[Legal Matters](#)