

Diagnostic Imaging Pathways - Ascites

Population Covered By The Guidance

This pathway provides guidance on how to image suspected ascites and determine its cause.

Date reviewed: January 2012

Date of next review: 2017/2018

Published: January 2012

Quick User Guide

Move the mouse cursor over the **PINK** text boxes inside the flow chart to bring up a pop up box with salient points.

Clicking on the **PINK** text box will bring up the full text.

The relative radiation level (RRL) of each imaging investigation is displayed in the pop up box.

SYMBOL	RRL	EFFECTIVE DOSE RANGE
	None	0
	Minimal	< 1 millisieverts
	Low	1-5 mSv
	Medium	5-10 mSv
	High	>10 mSv

Pathway Diagram

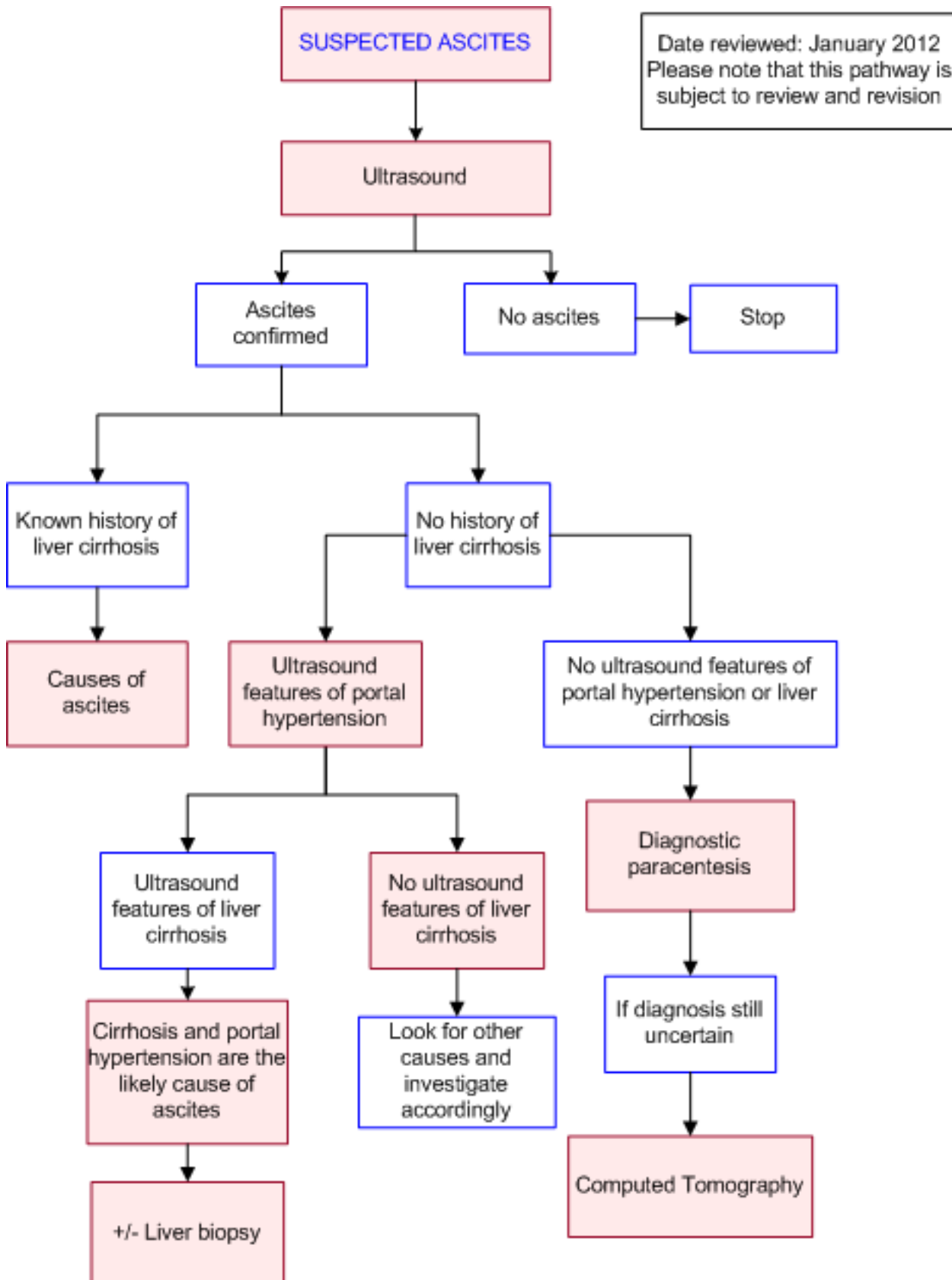
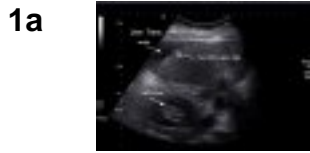

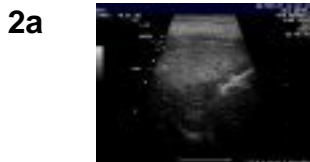
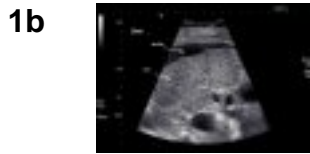
Image Gallery

Note: These images open in a new page



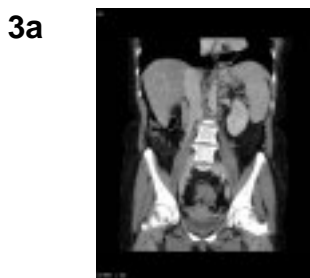
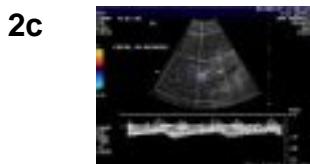
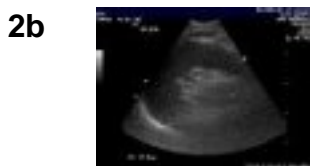Cirrhosis with Ascites

Image 1a and 1b (Ultrasound): Images from the same patient showing ascites surrounding the liver and a nodular hepatic surface consistent with cirrhosis.



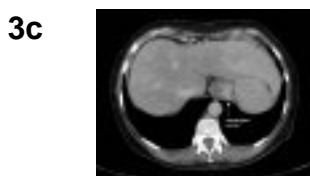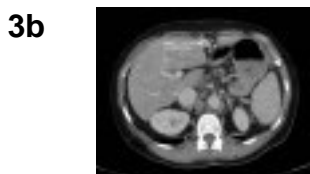Cirrhosis with Ascites

Image 2a, 2b and 2c (Ultrasound): Images from the same patient showing nodularity of the liver surface, coarse liver echotexture and small volume ascites (Image 2a). Splenomegaly due to portal hypertension (Image 2b) and reversal of flow in portal vein on doppler (Image 2c) are also present.



Portal Hypertension

Image 3a, 3b and 3c (Computed Tomography): Images from the same patient demonstrating portal hypertension. There is splenomegaly, varices adjacent to the gastric cardia and distal oesophagus (arrows) and a patent paraumbilical vein.



Teaching Points

- In suspected ascites, ultrasound is highly sensitive in confirming or refuting the diagnosis
- Ultrasound may show the cause of ascites, such as cirrhosis and portal hypertension or peritoneal metastases
- Ultrasound can guide diagnostic paracentesis for fluid analysis and cytology

Causes of Ascites

- Causes of ascites [17](#)
 - Cirrhosis - 81%
 - Cancer - 10%
 - Heart failure - 3%
 - Tuberculosis - 2%
 - Dialysis - 1%
 - Pancreatic disease - 1%
 - Other - 2%

Causes Of Cirrhosis And Portal Hypertension Seen On Ultrasonography

- Aetiology of hepatic cirrhosis [18](#)
 - Alcohol (60-70 percent)
 - Chronic hepatitis B or C (5-10 percent)
 - Biliary obstruction (5-10 percent)
 - Haemochromatosis (5-10 percent)
 - NASH (10 percent)
 - Other
 - Auto-immune
 - Drugs and toxins
 - Genetic metabolic disease

Computed Tomography (CT)

- Uses and features include:
 - Often has a complementary role with ultrasound in the evaluation of patients with ascites
 - Is a sensitive tool for the detection of ascites [4](#)
 - Provides a more complete evaluation of the abdomen and pelvis which is particularly useful in patients with an unknown source of ascites [3](#)
 - Unlike ultrasound is not impeded by a large amount of bowel gas
- Disadvantages
 - Involves exposure to radiation
 - Risk of contrast allergy and nephropathy if intravenous contrast is used

Diagnostic Paracentesis

- Is useful for [5](#)
 - Confirming the presence of ascites
 - Determining the cause of ascites
 - Determining whether the fluid is infected
 - Determining whether portal hypertension is present
 - A serum - ascitic albumin gradient (SAAG) >11g/l indicates ascites due to portal hypertension
 - A serum - ascitic albumin gradient (SAAG) <11g/l indicates ascites due to other causes

- Best done under ultrasound guidance if
 - There is only a small amount of fluid
 - The fluid is loculated
 - The patient has a gross coagulopathy or multiple scars
 - After a failed paracentesis done without ultrasound guidance

Ultrasound

- Uses and features include
 - Can confirm the presence of ascites as physical examination is only moderately accurate for diagnosis [1](#)
 - Can detect as little as a few millilitres of fluid located anterior to the liver or immediately below the diaphragm [2,3](#)
 - Can help determine the cause of ascites such as portal hypertension, cirrhosis, portal and hepatic vein thrombosis [4,6](#)
 - Can guide paracentesis and is particularly useful where there is only a small amount of fluid or the fluid is compartmentalised [4,5](#)
 - Has a sensitivity and specificity of at least 85% for the diagnosis of Budd-Chiari syndrome [8](#)
- Ultrasound features of portal hypertension include [14](#)
 - Collateral vessels - commonly gastroesophageal, paraumbilical, splenorenal and gastrosplenic veins [10,11](#)
 - Enlarged splanchnic veins [12](#)
 - Portal and splenic veins greater than 10mm in diameter (sensitivity and specificity of 82%) [13](#)
 - A patent paraumbilical vein (specificity of 100% and sensitivity of 82%) [15](#)
- Ultrasound features of liver cirrhosis include [14](#)
 - A coarsened, heterogeneous echo pattern
 - Increased parenchymal echogenicity
 - Nodularity of liver surface
- Limitations of ultrasound include [7](#)
 - Poor beam penetration in obese patients and those with multiple air-filled bowel loops
 - Low specificity for characterising liver lesions
 - Operator dependent

Liver Biopsy

- Referral for liver biopsy should be considered after a thorough non-invasive clinical, serological and radiological evaluation has failed to establish a cause of liver cirrhosis. Due consideration must be given to the risk/benefit profile prior to considering biopsy, as well as how biopsy results would change management [18](#)
- In a large prospective study which performed 354 liver biopsies for sustained abnormal liver function tests, 18% of patients had their management directly altered by the outcome of the biopsy [19](#)
- There is a significant false negative rate (10-50%) with percutaneous liver biopsy in the diagnosis of cirrhosis. Newer procedures that incorporate mini-laparoscopic techniques with direct visualisation of the liver has reduced this rate (15%) [20](#)

Causes Of Portal Hypertension With No Evidence Of Cirrhosis

- Causes of portal hypertension with no evidence of cirrhosis
 - Alcoholic hepatitis
 - Congestive cardiac failure
 - Massive hepatic metastasis
 - Constrictive pericarditis
 - Budd-Chiari syndrome
 - The Budd-Chiari Syndrome (BCS) refers to obstruction of hepatic venous outflow by a group of heterogeneous disorders [8,12](#)
 - Causes include [16](#)
 - Hypercoagulable states
 - Tumour invasion
 - Idiopathic
 - Doppler ultrasound has a sensitivity and specificity of at least 85% for the diagnosis and is the initial imaging modality of choice if the Budd-Chiari syndrome is suspected [17](#)
 - CT can assist in the diagnosis and compared to ultrasound, provides a more complete assessment of the abdomen
 - Hepatic venography is recommended if there is a strong clinical suspicion of Budd-Chiari syndrome, in the setting of a negative or inconclusive ultrasound result. The classical "spiderweb" pattern is often diagnostic [16](#)

Ultrasound Features Of Portal Hypertension

- Ultrasound features of portal hypertension include [14](#)
 - Collateral vessels - commonly gastroesophageal, paraumbilical, splenorenal and gastrosplenic veins [10,11](#)
 - Enlarged splanchnic veins [12](#)
 - Portal and splenic veins greater than 10mm in diameter (sensitivity and specificity of 82%) [13](#)
 - A patent paraumbilical vein (specificity of 100% and sensitivity of 82%) [15](#)

Causes Of Ascites In A Patient Known To Have Cirrhotic Liver Disease

- Causes of ascites in a patient known to have cirrhotic liver disease [9](#)
 - Progression of the underlying liver disease
 - Superimposed liver injury (such as alcoholic or viral hepatitis)
 - Development of hepatocellular carcinoma
 - Vascular thrombosis
 - Spontaneous bacterial peritonitis
 - Change to medications/diet

References

References are graded from Level I to V according to the Oxford Centre for Evidence-Based Medicine, Levels of Evidence. [Download the document](#)

1. Cattau EL, Benjamin SB, Knuff TE, Castell DO. **The accuracy of the physical examination in the diagnosis of suspected ascites.** JAMA. 1982;247:1164-6. (Level III evidence)
2. Goldberg BB, Goodman GA, Clearfield HR. **Evaluation of ascites by ultrasound.** Radiology. 1970;96:15-22. (Level II evidence). [View the reference](#)
3. Thoeni RF. **The role of imaging in patients with ascites.** AJR Am J Roentgenol. 1995;165:16-8. (Review article)
4. Olafsson S, Blei AT. **Diagnosis and management of ascites in the age of TIPS.** AJR Am J Roentgenol. 1995;165:9-15. (Review article)
5. Runyon BA. **Management of adult patients with ascites due to cirrhosis.** Hepatology. 1998;27:264-72. (Review article)
6. Malik A, Saxena NC. **Ultrasound in abdominal tuberculosis.** Abdom Imaging. 2003;28:574-9. (Level III evidence)
7. Taylor HM, Ros PR. **Hepatic Imaging.** Radiol Clin North Am. 1998;36:237-45. (Review article)
8. Bolondi L, Gaiani S, Li Bassi S, et al. **Diagnosis of Budd-Chiari syndrome by pulsed Doppler ultrasound.** Gastroenterology. 1991;100:1324-31. (Level III evidence)
9. Runyon BA, Montano AA, Akriviadis EA, et al. **The serum-ascites albumin gradient is superior to the exudates-transudate concept in the differential diagnosis of ascites.** Ann Intern Med. 1992;117:215-20. (Level III evidence)
10. Vilgrain V, Lebrech D, Menu Y et al. **Comparison between ultrasonographic signs and the degree of portal hypertension in patients with cirrhosis.** Gastrointest Radiol. 1990;15:218-22. (Level III evidence)
11. Subramanyam BR, Balthazar EJ, Madamba MR, et al. **Sonography of portosystemic venous collaterals in portal hypertension.** Radiology. 1983;146:161-6. (Level III evidence)
12. Vilgrain V. **Ultrasound of diffuse liver disease and portal hypertension.** Eur Radiol. 2001;11:1563-77. (Review article)
13. Sharma MP, Dasarathy S, Misra SC, Saksena S, Sundaram KR. **Sonographic signs in portal hypertension: a multivariate analysis.** Trop Gastroenterology. 1996;17:23-9. (Level III evidence)
14. Brown JJ, Naylor MJ, Yagan N. **Imaging of liver cirrhosis.** Radiology. 1997;202:1-16. (Review article)
15. Gibson RN, Gibson PR, Donlan JD, Clunie DA. **Identification of a patent paraumbilical vein by using Doppler sonography: importance in the diagnosis of portal hypertension.** AJR Am J Roentgenol. 1989;153:513-6. (Level II evidence). [View the reference](#)
16. Narayanan Menon KV, Shah V, Kamath PS. **Current concepts. the Budd-Chiari syndrome.** N Engl J Med. 2004;350:578-85. (Review article)
17. Kamath PS. **Budd Chiari syndrome: radiological findings.** Liver Transpl. 2006;12(11 Suppl 2):S21-2. (Review article)
18. Heidelbaugh J, Bruderly M. **Cirrhosis and chronic liver failure. Part I diagnosis and evaluation.** Am Fam Physician. 2006;74:756-62. (Review article)
19. Skelly M, James P, Ryder S. **Findings on liver biopsy to investigate abnormal liver function tests in the absence of diagnostic serology.** J Hepatol. 2001;35:195-9. (Level II Evidence). [View reference](#)
20. Helmreich-Becker I, Schimascher P, Denzer U. **Minilaproscopy in the diagnosis of cirrhosis: superiority in patients with child-pugh A and macronodular disease.** Endoscopy. 2003;35:55-60. (Level IV evidence)

Information for Consumers

Information from this website

Information from the Royal
Australian and New Zealand

	College of Radiologists' website
Radiation Risks of X-rays and Scans Computed Tomography (CT) Ultrasound	Computed Tomography (CT) Iodine-Containing Contrast Medium Radiation Risk of Medical Imaging During Pregnancy Radiation Risk of Medical Imaging for Adults and Children Ultrasound Ascitic Tap Image Guided Liver Biopsy

Copyright

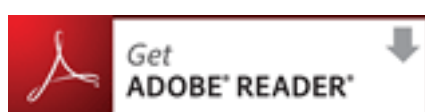
© Copyright 2015, Department of Health Western Australia. All Rights Reserved. This web site and its content has been prepared by The Department of Health, Western Australia. The information contained on this web site is protected by copyright.

Legal Notice

Please remember that this leaflet is intended as general information only. It is not definitive and The Department of Health, Western Australia can not accept any legal liability arising from its use. The information is kept as up to date and accurate as possible, but please be warned that it is always subject to change

File Formats

Some documents for download on this website are in a Portable Document Format (PDF). To read these files you might need to download Adobe Acrobat Reader.



[Legal Matters](#)