

Diagnostic Imaging Pathways - Thyroid Nodule (Incidental)

Population Covered By The Guidance

This pathway provides guidance on the imaging of adult patients with a thyroid nodule incidentally discovered on palpation or imaging.

Date reviewed: April 2016

Date of next review: 2017/2018

Published: August 2016

Quick User Guide

Move the mouse cursor over the **PINK** text boxes inside the flow chart to bring up a pop up box with salient points.

Clicking on the **PINK** text box will bring up the full text.

The relative radiation level (RRL) of each imaging investigation is displayed in the pop up box.

SYMBOL	RRL	EFFECTIVE DOSE RANGE
	None	0
	Minimal	< 1 millisieverts
	Low	1-5 mSv
	Medium	5-10 mSv
	High	>10 mSv

Pathway Diagram

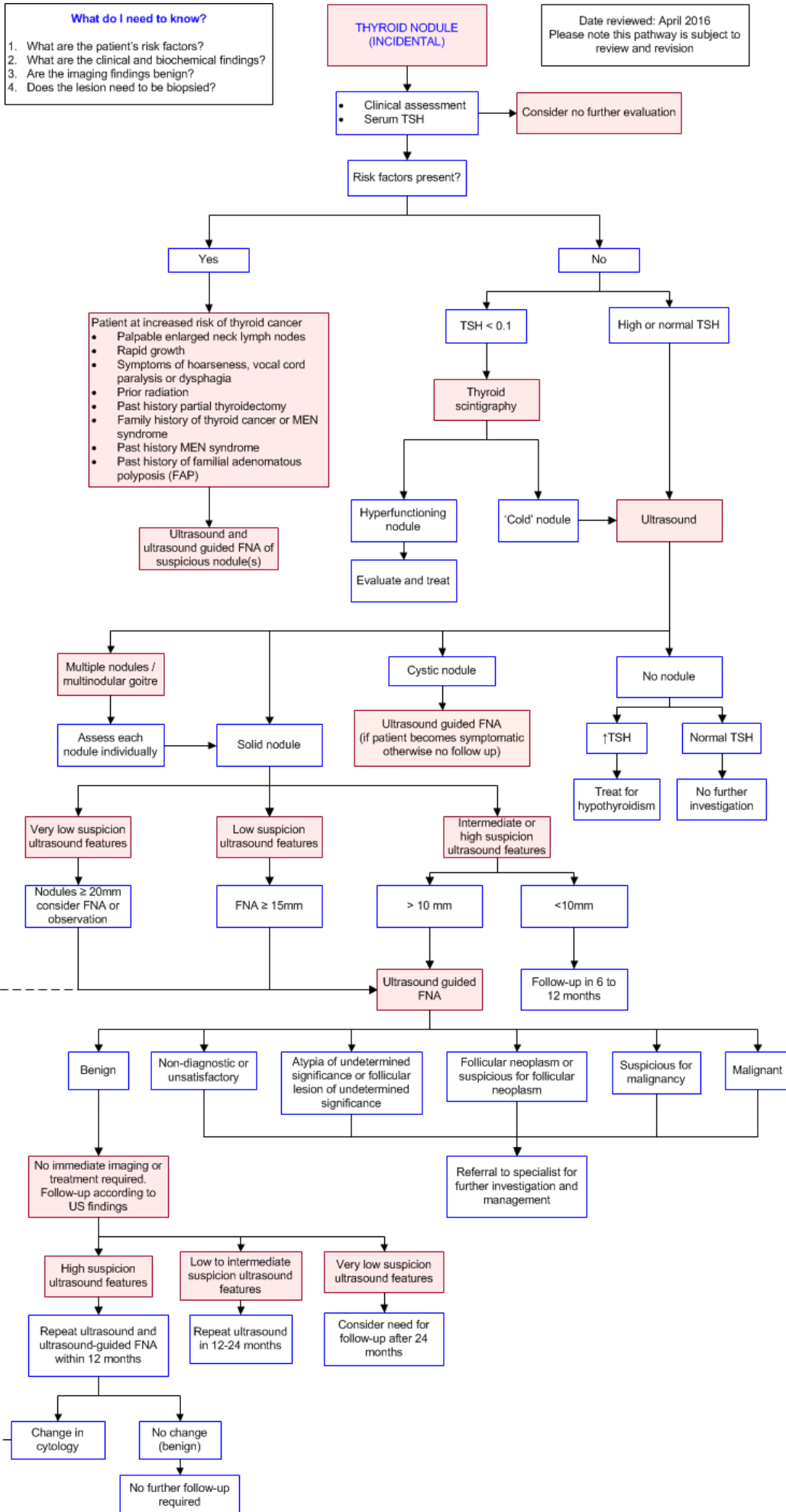
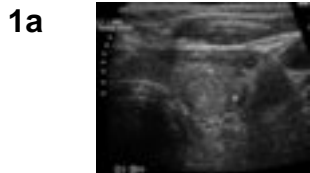

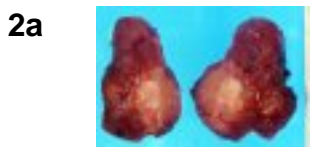
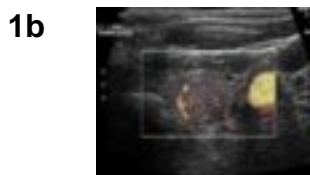Image Gallery

Note: These images open in a new page



Malignant Thyroid Nodule

Image 1a and 1b (Ultrasound): Left thyroid lobe nodule measuring up to 14mm which is predominantly high signal with a hypoechoic rim. It is hypervascular on colour Doppler. The features are consistent with a malignant nodule which was confirmed on histology.



Thyroid Carcinoma

Image 2a and 2b: Thyroidectomy specimen showing an irregular nodule invading through the thyroid parenchyma and into the external capsule.

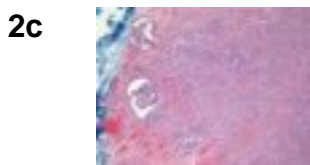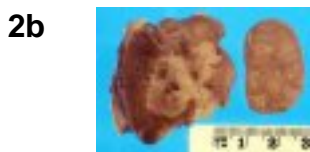
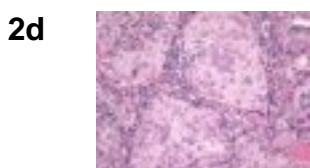


Image 2c (H&E, x2.5) and 2d (H&E, x20): Histological sections of a papillary thyroid carcinoma showing malignant cells forming papillary projections overlying fibrovascular cores. The cells demonstrate "Orphan Annie eye" nuclei with finely dispersed optically clear chromatin.



Teaching Points

- The evaluation of a thyroid nodule begins with clinical and biochemical assessment (specifically, serum thyroid stimulating hormone - TSH)
- Depending on the TSH level, the nodule should be further investigated with either nuclear scintigraphy (low TSH) or ultrasonography (high or normal TSH)
- On scintigraphy a nodule may be "hot" or "cold"
 - A 'hot' nodule can be managed medically, surgically or with radioiodine
 - A 'cold' nodule requires assessment with ultrasound ± fine needle aspiration (FNA)
- Thyroid sonography should be considered in all patients with known or suspected thyroid nodules. It is useful for assessing the morphology of the thyroid gland and nodule and for stratifying patients according to risk of malignancy



- FNA of thyroid nodules should be performed on all those nodules with suspicious US features and in patients at high risk of thyroid malignancy
- Key clinical questions that should be considered in the assessment of the incidental thyroid nodule include
 - Is the patient a high risk patient?
 - Does the imaged nodule represent a cystic nodule, solid nodule or nodule of a multinodular goitre (MNG)?
 - How big is the thyroid nodule and does are there any suspicious features on ultrasound?
 - Is the thyroid nodule an active nodule?
- Where a patient has FDG PET / CT for staging / localisation of metastatic disease often this can reveal focal uptake in thyroid tissue. Where this is the case it is prudent to further investigate this result with thyroid antibodies, ultrasound and FNA if the initial investigations are suggestive of a potentially malignant process
- Where a dominant nodule is identified in a multinodular goitre that is growing in size or has suspicious features this should be investigated further with FNA. Each nodule of a multinodular goitre should be assessed individually for consideration of FNA

Thyroid Nodule (Incidental)

- Thyroid nodules are defined as discrete lesions within the thyroid gland that are radiologically distinct from the surrounding thyroid parenchyma. They represent a common diagnostic challenge. Palpable nodules have been reported to occur in 5.3% of women and 0.8% of men [1](#) and in 20% to 76% of ultrasound examinations performed in the adult population. [2,3,4](#) In many cases they are discovered incidentally on carotid Doppler ultrasound. Incidental thyroid nodules (ITNs) are also found in about 16% of CT and MRI scans which include the thyroid region [3](#)
- Although thyroid nodules are common, only around 4-7% of all nodules are malignant, [5](#) rising to about 15% in nodules larger than 10mm that are subjected to FNA. [6](#) This may be an overestimate given that obviously benign nodules, such as pure cysts are not usually subject to FNA. The other causes of thyroid nodules include colloid nodules, thyroid cysts, thyroiditis and benign follicular neoplasms
- Thyroid cancers may be of four types: papillary (85%), follicular (11%), medullary (3%) and anaplastic (1%) [7](#)
- The numbers of thyroid cancers diagnosed have increased as a result of being found incidentally on imaging, some might say to epidemic proportions. Thyroid cancer rates have increased 2.4-fold between 1973 and 2002 [8](#) and doubled between 2000 and 2009 [9](#)
- The vast majority of these are papillary type; these lesions, if they are less than 2 cm in size have an excellent prognosis – 99% of patients are alive at 20 years. Patients with small lesions, no personal history of radiation exposure and no family history of thyroid cancer, who have favourable signs at thyroid ultrasound, have a low risk of progression. [7](#) Although the incidence of papillary thyroid cancer has increased, the mortality rate has remained stable. In addition, autopsy series have shown a high prevalence of subclinical papillary thyroid cancers. [7](#) This suggests that there is a problem of over-diagnosis and that many individuals will die with their thyroid cancer rather than of it. This has led to suggestions for a change in nomenclature; to rename low risk papillary lesions as “micropapillary lesions of indolent course” (microPLICs). MicroPLICs are defined as low-risk lesions (smaller than 20 mm in patients with no family history or radiation exposure and no ultrasound evidence of extraglandular invasion). [7](#) However it should be noted that this term is not yet endorsed by any expert group. Patients with these lesions may be offered surveillance rather than active treatment [7,10](#)
- Papillary thyroid microcarcinomas have an excellent prognosis. Hay et al followed up 900 patients with papillary thyroid microcarcinomas (WHO nomenclature) for a mean of 17 years and reported a

- mortality of 0.3% [11,28](#)
- There are several international evidence and expert-consensus based guidelines for the management of thyroid nodules which provide sources for the present guideline [3,13,15,28](#),
- All patients with ITNs should undergo clinical assessment and serum thyroid stimulating hormone (TSH) measurement
- Patients with increased risk of thyroid cancer should proceed to US guided FNA
- Patients at average personal risk of thyroid cancer with low TSH levels should undergo thyroid scintigraphy
- Patients at average personal risk of thyroid cancer with normal or high TSH levels should undergo US of the thyroid

Consider No Further Evaluation

- In patients without systemic symptoms or signs and without local symptoms of thyroid disease, no risk factors for thyroid cancer and particularly older patients with co-morbidities, strong consideration should be given to no further investigation. Patients with lesions appearing invasive or with local nodal enlargement should be further evaluated
- Even in those patients who have non-benign nodules, the vast majority of these are papillary type lesions which, if they are less than 2 cm in size have an excellent prognosis; 99% of patients are alive at 20 years. Patients with small lesions, no personal history of radiation exposure and no family history of thyroid cancer, who have favourable signs at thyroid ultrasound, have a low risk of progression. [7](#) Although the incidence of papillary thyroid cancer has increased, the mortality rate has remained stable. In addition, autopsy series have shown a high prevalence of subclinical papillary thyroid cancers. [7](#) This suggests that there is a problem of over-diagnosis and that many individuals will die with their thyroid cancer rather than of it. This has led to suggestions for a change in nomenclature - to rename low risk papillary lesions (< 2 cm, no historical risk factors and no US signs of extra-glandular invasion) as "micropapillary lesions of indolent course" (microPLICs) [7](#)

Patients At Increased Risk Of Thyroid Cancer

- Prior radiation
- Rapid growth of a thyroid nodule
- Symptoms of hoarseness, vocal cord paralysis or dysphagia
- Family history of thyroid cancer or multiple endocrine neoplasia (MEN) syndromes
- Personal history of MEN syndrome
- Past history of partial thyroidectomy
- Palpable cervical lymph nodes
- Young patient < 35 (particularly male)

Thyroid Scintigraphy

- With the widespread use of fine needle aspiration biopsy in the evaluation of thyroid nodules, the role of thyroid scintigraphy has diminished. However, it still has an important role in the patient with a palpable thyroid nodule and suppressed thyroid stimulation hormone (TSH) level [28](#)
- Scintigraphy is most commonly done with technetium-99m pertechnetate, although radioiodine I-123 is sometimes used [22](#)

- It is useful for classifying nodules as hyperfunctioning, hypofunctional or indeterminate according to the visible pattern of tracer uptake [23](#)
- Hyperfunctioning nodules are rarely malignant and account for approximately 5-10% of thyroid nodules. Patients with hyperfunctioning nodules are usually managed with either surgery or radioiodine ablation
- Approximately 90-95% of palpable nodules will be hypofunctional or indeterminate on thyroid scintigraphy and these nodules should proceed to US [22](#)
- Information for consumers on [Thyroid Scintigraphy](#)

Ultrasound

- All published evidence-based guidelines agree that ultrasound is the imaging modality of choice for the evaluation of the morphology of the thyroid gland. The need for imaging in asymptomatic individuals should be tempered by the known “benign” course of the majority of papillary cancers (which make up 90-95%) of thyroid cancers. Patients with unrelated co-morbidities and elderly patients may therefore not require further investigation of their ITN [7](#)
- Clinically “solitary” nodules are in fact found to be part of a multinodular process in up to 70% of cases when US is performed. Patients with multiple thyroid nodules have the same risk of malignancy as those with solitary nodules. However, one large study found that a solitary nodule had a higher likelihood of malignancy than did a non-solitary nodule ($p < 0.01$), although the risk of malignancy per patient was the same and independent of the number of nodules [6](#)
- Thyroid scintigraphy should also be considered in patients with multiple thyroid nodules, if the serum TSH is in the low or low-normal range, with fine needle aspiration (FNA) being performed on those nodules that are hypofunctioning [28](#)
- Nodules should be assessed individually for suggestion of malignancy and those nodules which differ sonographically to surrounding nodules, or those with features of malignancy should undergo FNA
- All major guidelines suggest US-guided FNA on nodules with suspicious imaging features
- Features on ultrasound that suggest malignancy include [3,9,13,15,24,25,26,27,28](#)
 - Increased height to width ratio
 - Irregular margins (infiltrative, spiculated or microlobulated)
 - Microcalcifications
 - Evidence of extrathyroidal extension (cervical lymph nodes, distant metastases)
 - Solid hypoechoic nodule
 - Increased blood flow centrally
 - Absence of “halo”
- Low to moderate quality evidence suggests that individual ultrasound features are not accurate predictors of thyroid cancer. [24](#) However, the diagnostic accuracy of individual ultrasound features varies which must be considered when assessing the overall risk of malignancy. In a systematic review and meta-analysis of 31 studies looking at the accuracy of thyroid nodule ultrasound features in the prediction of thyroid cancer the high risk features which had the highest diagnostic odds ratio (DOR) and specificities include [24](#)
 - Taller than wider (DOR 11.14 95% CI 6.6-18.9, specificity 93%)
 - Infiltrative margins (DOR 6.89 95% CI 3.35-14.1, specificity 79%)
 - Internal calcifications (DOR 6.78 95% CI 4.48-10.24, specificity 81%)
- Features that are highly specific for benignity, and therefore will often militate against FNA include [26,27,28](#)
 - Spongiform configuration
 - Cyst with colloid clot
 - Giraffe pattern

- Diffuse hyperechogenicity
- Rather than rely on individual sonographic features, pattern recognition can be applied to identify benign nodules. In one series recognition of specific morphologic patterns was found to be an accurate method of identifying benign thyroid nodules that do not require cytologic evaluation and would have obviated more than 60% of thyroid biopsies [27](#)
- Management of nodules < 10 mm in size should be considered based upon patient demographics, risk factors for malignancy and US findings. The accuracy of the features described that help distinguish benign and malignant nodules is dependent on size and reduced for nodules < 10 mm
- The incidence of cancer in nodules less than and greater than 10mm is not significantly different. However there is evidence that the micropapillary carcinomas that are the most frequently discovered cancers in the small lesions, rarely progress to clinically significant lesions. [7](#) FNA is not recommended routinely for nodules < 10 mm unless there are suspicious US features or the patient has clinical risk factors for thyroid cancer [28](#)
- US-guided FNA of nodules should be performed on patients with increased personal risk of thyroid cancer [3](#)
- Qualitative sonoelastography (ultrasound elastography) is an additional method of assessment which looks at tissue distortion when an external force is applied. [29](#) The most common method of reporting this modality is an elasticity score, usually between 1-4 or 1-5 with lower numbers representing greater elasticity and higher numbers representing greater firmness. The more firm the thyroid nodule, the increased likelihood of malignancy. [30](#) Quantitative approaches like strain ratio measurement and shear-wave elastography are new developments in sonoelastography [30](#)
- Sonoelastography has a high sensitivity and specificity for the identification of thyroid nodules with the use of qualitative methods (elasticity score) of comparable sensitivity and specificity to quantitative methods (strain ratio). [31](#) The performance of sonoelastography distinguishing between benign and malignant thyroid nodules compared with FNA cytologic and histopathologic examination has revealed that sonoelastography is an excellent adjunctive screening tool for characterising thyroid nodules with a negative predictive value of an elasticity score of 1 at approximately 0.995. Given this the use of sonoelastography to determine which nodules are benign and not requiring FNA and therefore can be clinically followed up, is a promising area
- Whilst sonoelastography is a promising area it is yet to achieve mainstream use in radiological practice. This is mainly due to factors including expertise, cost and logistical considerations. Additionally despite its potential as a screening tool, appropriate follow up for those assessed by elastography to have benign nodules have not been delineated and require further consideration

Ultrasound Guided Fine Needle Aspiration (FNA)

- Ultrasonography cannot accurately differentiate benign from malignant thyroid nodules and fine needle aspiration biopsy should be used selectively to avoid over-diagnosis and over-treatment. If the clinician follows current guidelines for the investigation of thyroid incidentalomas a proportion of malignant incidentalomas will inevitably be missed. Whether this is clinically important is controversial as it is generally agreed that the natural history of small incidental thyroid cancers is indolent. [7,34](#) Therefore, a one-size-fits-all approach is simply not practical. Instead, surveillance strategies should be individualised based on a nodule's sonographic appearance. [35](#) Management of nodules < 10 mm in size should also be considered based upon patient demographics, risk factors for malignancy and US findings
- Fine needle aspiration (FNA) is the most accurate and cost-effective method for evaluating thyroid nodules [28](#) and is advised in patients with increased personal risk of thyroid cancer [9](#)
- All major guidelines suggest US-guided FNA for nodules with suspicious imaging features. [3,15,25,28,36](#) Substantial growth can be defined as sonographic evidence of growth (20% increase in at least two nodule dimensions with a minimal increase of 2 mm or more than a 50% change in



- volume) or development of new suspicious sonographic features [28](#)
- However, FNA is not indicated for purely cystic lesions and is likely to be unnecessary in a diffusely enlarged gland with multiple nodules of similar US appearance without intervening parenchyma [15](#)
- In order to standardize the terminology used for reporting thyroid cytopathology from FNA, the National Cancer Institute Thyroid Fine-Needle Aspiration State of the Science Conference was held in Bethesda, Maryland in 2007
- The Bethesda System for Reporting Thyroid Cytopathology (TBSRTC) was created using the recommendations resulting from this conference [37](#)
- TBSRTC recommends that each report begin with one of six general categories which each have an estimation of risk of malignancy (based on evidence and expert opinion) [28](#)
- A meta-analysis of eight studies confirmed the validity of TBSRTC with a reported sensitivity of over 97%, a NPV for the benign category of 96.3% and a PPV for the malignant category of 98.6% [38](#)
- The risk of malignancy for each category showed significant variability and it is recommended that risk of malignancy should be independently defined at each cytology centre or institution [28](#)

Diagnostic Category	Estimated risk of malignancy by Bethesda system (%)	Actual risk of malignancy in surgically excised nodules (%)
Non-diagnostic or unsatisfactory	1-4	9-32
Benign	0-3	1-10
Atypia of undetermined significance or follicular lesion of undetermined significance	5-15	6-48
Follicular neoplasm or suspicious for a follicular neoplasm	15-30	14-34
Suspicious for malignancy	60-75	53-97
Malignant	97-99	94-100

- A benign result after US and FNA is reassuring, but a small risk of a false reassurance exists. This risk is much lower after a second benign FNA result. [39](#) Given this, international guidelines agree that some follow-up is sometimes appropriate depending on the ultrasound appearance on the nodule
- British guidelines recommend that patients with benign FNA results and benign ultrasound appearances do not require repeat FNA. On the other hand, they recommend that nodules with benign FNA results but suspicious ultrasound features should undergo repeat FNA. They are not specific about timing of follow-up [36](#)
- American guidelines recommend that following an initial benign FNA result
 - Nodules with highly suspicious US features should have repeat US and FNA within 1 year
 - Nodules with low-to-intermediate suspicious US features should have repeat US at 12-24 months, with growth or increasingly suspicious features triggering either FNA or further US surveillance [28](#)
- The American guidelines also state that

- There is insufficient evidence to guide firm follow-up recommendations for lesions with very low suspicion ultrasound findings and a single benign FNA result. It is not clear that further ultrasound is needed, but if it is performed, it should not routinely be done earlier than 2 years
- Nodules that have had benign cytology findings on two separate FNAs do not require further ultrasound surveillance [28](#)
- An FNA is a relatively painless procedure that is sometimes done without local anaesthesia. A fine needle (23 gauge or thinner) is used and specimens are typically taken from several parts of the thyroid nodule. These tissue specimens are smeared immediately onto pathology slides for further staining and evaluation
- Information for consumers on [Fine Needle Aspiration Biopsy](#)

Multiple Nodules / Multinodular Goitre

- Clinically “solitary” nodules are in fact found to be part of a multinodular process in up to 70% of cases when US is performed. Patients with multiple thyroid nodules have the same risk of malignancy as those with solitary nodules. However, one large study found that a solitary nodule had a higher likelihood of malignancy than did a non-solitary nodule ($p < 0.01$), although the risk of malignancy per patient was the same and independent of the number of nodules [6](#)
- Thyroid scintigraphy should be considered in patients with multiple thyroid nodules, if the serum TSH is in the low or low-normal range, with FNA being performed on those nodules that are hypofunctioning [1](#)
- The management of patients with multinodular goitre and thyroid nodules has not yet been fully delineated in regards to which nodules should be biopsied
- Management strategies range from FNA of the dominant nodule to FNA of multiple nodules
- Where a dominant nodule is noted to be growing and / or changing in features, FNA should be undertaken [16](#)
- Focusing on the most prominent nodule has been found to be the most predictive for malignancy in the few studies that have investigated the topic, though the diagnostic accuracy results of these studies was poor [17,18,19](#)
- If a nodule has grown steadily, become distinctly dominant or has changed in nature then its risk for malignancy has been shown to be the same as that of a solitary nodule [20,21](#)

Degree of Suspicious Features on Ultrasound

- The American Institute of Ultrasound In Medicine 2013 Guidelines for Thyroid and Parathyroid Ultrasound Examination state that thyroid abnormalities should be imaged in a way that allows for reporting and documentation of the following [32](#)
 - The location, size, number and character of significant abnormalities, including measurements of nodules and focal abnormalities in three dimensions
 - The localised or diffuse nature of any thyroid abnormality, including assessment of overall gland vascularity
 - The sonographic features of any thyroid abnormality with respect to echogenicity, composition (degree of cystic change), margins (smooth or irregular), presence and type of calcification (if present) and other relevant sonographic patterns
 - The presence and size of any abnormal lymph node in the lateral compartment of the neck
- Thyroid nodules can then be classified into five patterns according to the combination of ultrasound features present. [28](#) This method provides effective malignancy risk stratification for thyroid

nodules, with a sensitivity of 95.3% and NPV 97.3% [33](#)

High Suspicion (Malignancy Risk > 70-90%) [28](#)

- Solid hypo-echoic nodule with one or more of
 - Increased height to width ratio
 - Irregular margins (infiltrative, spiculated or microlobulated)
 - Microcalcifications
 - Evidence of extrathyroidal extension (cervical lymph nodes, distant metastases)

Intermediate Suspicion (Malignancy Risk 10-20%)

- Solid hypoechoic nodule with
 - A smooth, regular margin and
 - No other suspicious features

Low Suspicion (Malignancy Risk 5-10%)

- Solid hyper-echoic or iso-echoic nodule with
 - Regular margins
 - No microcalcifications
 - No extra-thyroid extension
 - No other suspicious features

Very Low Suspicion (Malignancy Risk ? 3%)

- Spongiform configuration
- Partially cystic nodule
- No other suspicious features

Benign (Malignancy Risk ? 1%)

- Purely cystic nodule

Follow-up

- A benign result after US and FNA is reassuring, but a small risk of a false reassurance exists. This risk is much lower after a second benign FNA result. [39](#) Given this, international guidelines agree that some follow-up is sometimes appropriate depending on the ultrasound appearance on the nodule
- British guidelines recommend that patients with benign FNA results and benign ultrasound appearances do not require repeat FNA. On the other hand, they recommend that nodules with benign FNA results but suspicious ultrasound features should undergo repeat FNA. They are not specific about timing of follow-up [36](#)
- American guidelines recommend that following an initial benign FNA result
 - Nodules with highly suspicious US features should have repeat US and FNA within one year
 - Nodules with low-to-intermediate suspicious US features should have repeat US at 12-24 months, with growth or increasingly suspicious features triggering either FNA or further US

surveillance [28](#)

- The American guidelines also state that
 - There is insufficient evidence to guide firm follow-up recommendations for lesions with very low suspicion ultrasound findings and a single benign FNA result. It is not clear that further ultrasound is needed, but if it is performed, it should not routinely be done earlier than two years
 - Nodules that have had benign cytology findings on two separate FNAs do not require further ultrasound surveillance [28](#)

References

Date of literature search: April 2016

The search methodology is available on request. [Email](#)

References are graded from Level I to V according to the Oxford Centre for Evidence-Based Medicine, Levels of Evidence. [Download the document](#)

1. Jin J, McHenry CR. **Thyroid incidentaloma**. Best Pract Res Clin Endocrinol Metab. 2012;26(1):83-96. (Review article). [View the reference](#)
2. Brander A, Viikinkoski P, Nickels J, Kivisaari L. **Thyroid gland: US screening in a random adult population**. Radiology. 1991;181(3):683-7. (Level II evidence). [View the reference](#)
3. Gharib H, Papini E, Paschke R, Duick DS, Valcavi R, Hegedus L, et al. **American Association of Clinical Endocrinologists, Associazione Medici Endocrinologi, and European Thyroid Association Medical guidelines for clinical practice for the diagnosis and management of thyroid nodules: executive summary of recommendations**. Endocr Pract. 2010;16(3):468-75. (Guidelines). [View the reference](#)
4. Mackenzie EJ, Mortimer RH. **6: Thyroid nodules and thyroid cancer**. Med J Aust. 2004;180(5):242-7. (Review article). [View the reference](#)
5. Lin JD, Chao TC, Huang BY, Chen ST, Chang HY, Hsueh C. **Thyroid cancer in the thyroid nodules evaluated by ultrasonography and fine-needle aspiration cytology**. Thyroid. 2005;15(7):708-17. (Level II evidence). [View the reference](#)
6. Frates MC, Benson CB, Doubilet PM, Kunreuther E, Contreras M, Cibas ES, et al. **Prevalence and distribution of carcinoma in patients with solitary and multiple thyroid nodules on sonography**. J Clin Endocrinol Metab. 2006;91(9):3411-7. (Level II evidence). [View the reference](#)
7. Brito JP, Morris JC, Montori VM. **Thyroid cancer: zealous imaging has increased detection and treatment of low risk tumours**. BMJ. 2013;347:f4706. (Review article). [View the reference](#)
8. Davies L, Welch HG. **Increasing incidence of thyroid cancer in the United States, 1973-2002**. JAMA. 2006;295(18):2164-7. (Level II evidence). [View the reference](#)
9. Hobbs HA, Bahl M, Nelson RC, Kranz PG, Esclamado RM, Wnuk NM, et al. **Journal Club: incidental thyroid nodules detected at imaging: can diagnostic workup be reduced by use of the Society of Radiologists in Ultrasound recommendations and the three-tiered system?** AJR Am J Roentgenol. 2014;202(1):18-24. (Level III evidence). [View the reference](#)
10. Ito Y, Tomoda C, Uruno T, Takamura Y, Miya A, Kobayashi K, et al. **Papillary microcarcinoma of the thyroid: how should it be treated?** World J Surg. 2004;28(11):1115-21. (Level III evidence). [View the reference](#)
11. Hay ID, Hutchinson ME, Gonzalez-Losada T, McIver B, Reinalda ME, Grant CS, et al. **Papillary thyroid microcarcinoma: a study of 900 cases observed in a 60-year period**. Surgery. 2008;144(6):980-7; discussion 7-8. (Level II evidence). [View the reference](#)
12. American Thyroid Association. **Revised American Thyroid Association management**

- guidelines for patients with thyroid nodules and differentiated thyroid cancer.** 2009 [cited 2015 November 19]. [View the reference](#)
13. Levine RA. **Current guidelines for the management of thyroid nodules.** *Endocr Pract.* 2012;18(4):596-9. (Guidelines). [View the reference](#)
 14. Cooper DS, Doherty GM, Haugen BR, Kloos RT, Lee SL, Mandel SJ, et al. **Revised American Thyroid Association management guidelines for patients with thyroid nodules and differentiated thyroid cancer.** *Thyroid.* 2009;19(11):1167-214. (Guidelines). [View the reference](#)
 15. Frates MC, Benson CB, Charboneau JW, Cibas ES, Clark OH, Coleman BG, et al. **Management of thyroid nodules detected at US: Society of Radiologists in ultrasound consensus conference statement.** *Radiology.* 2005;237(3):794-800. (Consensus statement). [View the reference](#)
 16. Eng CY, Quraishi MS, Bradley PJ. **Management of thyroid nodules in adult patients.** *Head & Neck Oncology.* 2010;2:11. (Review article). [View the reference](#)
 17. Al-Yaarubi S, Farhan H, Al-Futaisi A, Al-Qassabi S, Al-Rasadi K, Al-Riyami S, et al. **Accuracy of ultrasound-guided fine-needle aspiration cytology for diagnosis of carcinoma in patients with multinodular goiter.** *Indian J Endocrinol Metab.* 2011;15(Suppl2):S132-S5. (Level III evidence). [View the reference](#)
 18. Hurley DL, Gharib H. **Evaluation and management of multinodular goiter.** *Otolaryngol Clin North Am.* 1996;29(4):527-40. (Review article). [View the reference](#)
 19. Rios A, Rodriguez JM, Galindo PJ, Montoya M, Tebar FJ, Sola J, et al. **Utility of fine-needle aspiration for diagnosis of carcinoma associated with multinodular goitre.** *Clin Endocrinol (Oxf).* 2004;61(6):732-7. (Level II evidence). [View the reference](#)
 20. Mandreker SR, Nadkarni NS, Pinto RG, Menezes S. **Role of fine needle aspiration cytology as the initial modality in the investigation of thyroid lesions.** *Acta Cytol.* 1995;39(5):898-904. (Level II evidence). [View the reference](#)
 21. Tollin SR, Mery GM, Jelveh N, Fallon EF, Mikhail M, Blumenfeld W, et al. **The use of fine-needle aspiration biopsy under ultrasound guidance to assess the risk of malignancy in patients with a multinodular goiter.** *Thyroid.* 2000;10(3):235-41. (Level III evidence). [View the reference](#)
 22. Hegedus L. **Clinical practice. The thyroid nodule.** *N Engl J Med.* 2004;351(17):1764-71. (Review article). [View the reference](#)
 23. Meier DA, Kaplan MM. **Radioiodine uptake and thyroid scintiscanning.** *Endocrinol Metab Clin North Am.* 2001;30(2):291-313, viii. (Review article). [View the reference](#)
 24. Brito JP, Gionfriddo MR, Al Nofal A, Boehmer KR, Leppin AL, Reading C, et al. **The accuracy of thyroid nodule ultrasound to predict thyroid cancer: systematic review and meta-analysis.** *J Clin Endocrinol Metab.* 2014;99(4):1253-63. (Level II evidence). [View the reference](#)
 25. Kim HG, Moon HJ, Kwak JY, Kim EK. **Diagnostic accuracy of the ultrasonographic features for subcentimeter thyroid nodules suggested by the revised American Thyroid Association guidelines.** *Thyroid.* 2013;23(12):1583-9. (Level III evidence). [View the reference](#)
 26. Moon WJ, Jung SL, Lee JH, Na DG, Baek JH, Lee YH, et al. **Benign and malignant thyroid nodules: US differentiation - multicenter retrospective study.** *Radiology.* 2008;247(3):762-70. (Level II evidence). [View the reference](#)
 27. Bonavita JA, Mayo J, Babb J, Bennett G, Oweity T, Macari M, et al. **Pattern recognition of benign nodules at ultrasound of the thyroid: which nodules can be left alone?** *AJR Am J Roentgenol.* 2009;193(1):207-13. (Level III evidence). [View the reference](#)
 28. Haugen BRM, Alexander EK, Bible KC, Doherty G, Mandel SJ, Nikiforov YE, et al. **2015 American Thyroid Association management guidelines for adult patients with thyroid nodules and differentiated thyroid cancer.** *Thyroid.* 2015:[Epub ahead of print]. (Guidelines). [View the reference](#)
 29. Garra BS. **Imaging and estimation of tissue elasticity by ultrasound.** *Ultrasound Q.* 2007;23(4):255-68. (Review article). [View the reference](#)
 30. Ghajarzadeh M, Sodagari F, Shakiba M. **Diagnostic accuracy of sonoelastography in detecting**



- malignant thyroid nodules: a systematic review and meta-analysis.** AJR Am J Roentgenol. 2014;202(4):W379-89. (Level I evidence). [View the reference](#)
31. Sun J, Cai J, Wang X. **Real-time ultrasound elastography for differentiation of benign and malignant thyroid nodules: a meta-analysis.** J Ultrasound Med. 2014;33(3):495-502. (Level I evidence). [View the reference](#)
32. **Thyroid and parathyroid ultrasound examination [Internet].** American Institute of Ultrasound in Medicine; 2013 [cited 2016 April 18]. [View the reference](#)
33. Yoon JH, Lee HS, Kim EK, Moon HJ, Kwak JY. **Malignancy risk stratification of thyroid nodules: comparison between the thyroid imaging reporting and data system and the 2014 American Thyroid Association management guidelines.** Radiology. 2016;278(3):917-24. (Level II evidence). [View the reference](#)
34. Aspinall SR, Ong SG, Wilson MS, Lennard TW. **How shall we manage the incidentally found thyroid nodule?** Surgeon. 2013;11(2):96-104. (Review article). [View the reference](#)
35. Vega C. **Most benign thyroid nodules show no growth at 5 years.** New York: Medscape; 2015 [cited 2015 November]
36. Perros P, Boelaert K, Colley S, Evans C, Evans RM, Gerrard Ba G, et al. **Guidelines for the management of thyroid cancer.** Clin Endocrinol (Oxf). 2014;81 Suppl 1:1-122. (Guidelines). [View the reference](#)
37. Cibas ES, Ali SZ. **The Bethesda system for reporting thyroid cytopathology.** Am J Clin Pathol. 2009;132(5):658-65. (Consensus article). [View the reference](#)
38. Bongiovanni M, Spitale A, Faquin WC, Mazzucchelli L, Baloch ZW. **The Bethesda system for reporting thyroid cytopathology: a meta-analysis.** Acta Cytol. 2012;56(4):333-9. (Level I evidence). [View the reference](#)
39. Oertel YC, Miyahara-Felipe L, Mendoza MG, Yu K. **Value of repeated fine needle aspirations of the thyroid: an analysis of over ten thousand FNAs.** Thyroid. 2007;17(11):1061-6. (Level III/IV evidence). [View the reference](#)

Information for Consumers

Information from this website	Information from the Royal Australian and New Zealand College of Radiologists' website
<p>Consent to Procedure or Treatment</p> <p>Radiation Risks of X-rays and Scans</p> <p style="padding-left: 40px;">Ultrasound</p> <p style="padding-left: 40px;">Ultrasound (Doppler)</p>	<p>Radiation Risk of Medical Imaging During Pregnancy</p> <p>Radiation Risk of Medical Imaging for Adults and Children</p> <p style="padding-left: 40px;">Ultrasound</p> <p>Thyroid Fine Needle Aspiration (FNA)</p> <p style="padding-left: 40px;">Nuclear Medicine</p> <p style="padding-left: 40px;">Nuclear Medicine Thyroid Scan</p>

Copyright

© Copyright 2015, Department of Health Western Australia. All Rights Reserved. This web site and its content has been prepared by The Department of Health, Western Australia. The information contained on this web site is protected by copyright.

Legal Notice

Please remember that this leaflet is intended as general information only. It is not definitive and The Department of Health, Western Australia can not accept any legal liability arising from its use. The information is kept as up to date and accurate as possible, but please be warned that it is always subject to change

File Formats

Some documents for download on this website are in a Portable Document Format (PDF). To read these files you might need to download Adobe Acrobat Reader.



[Legal Matters](#)